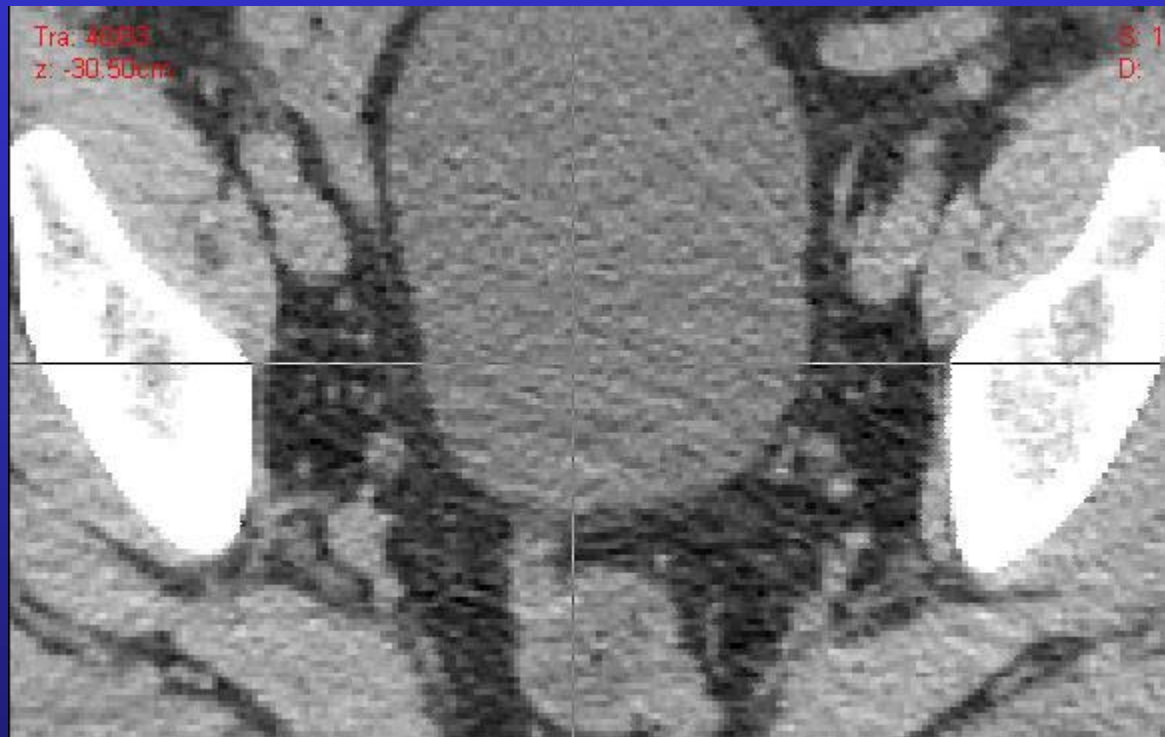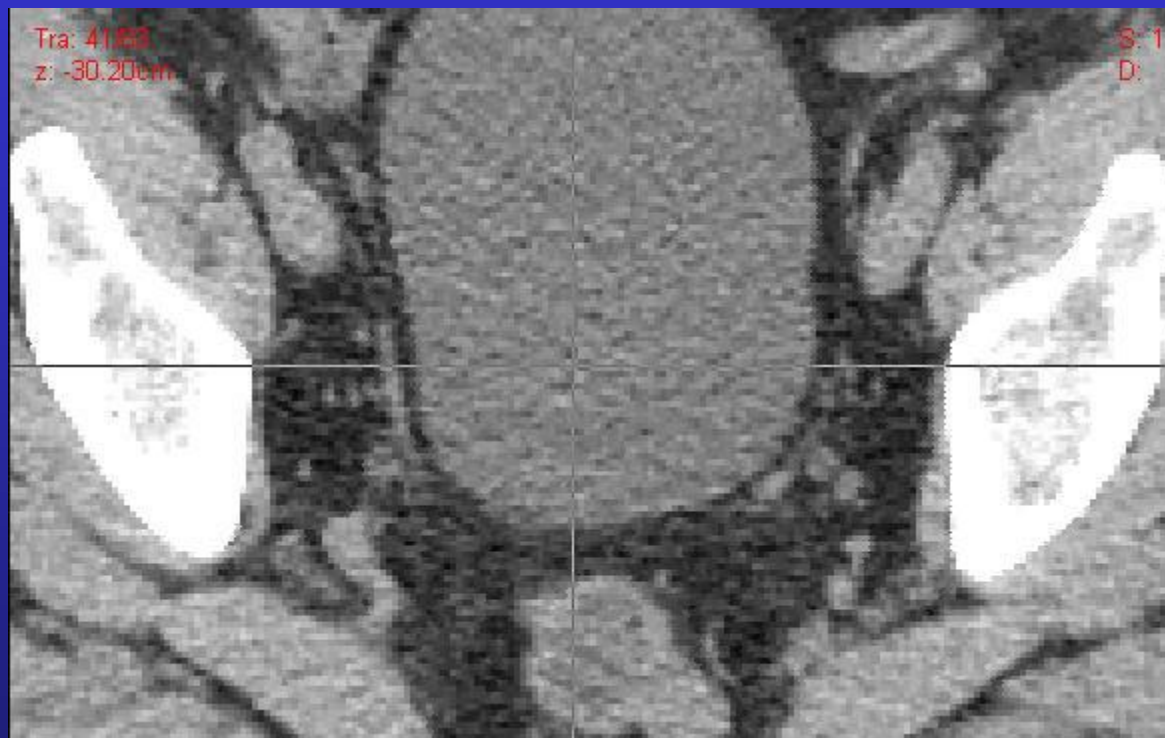


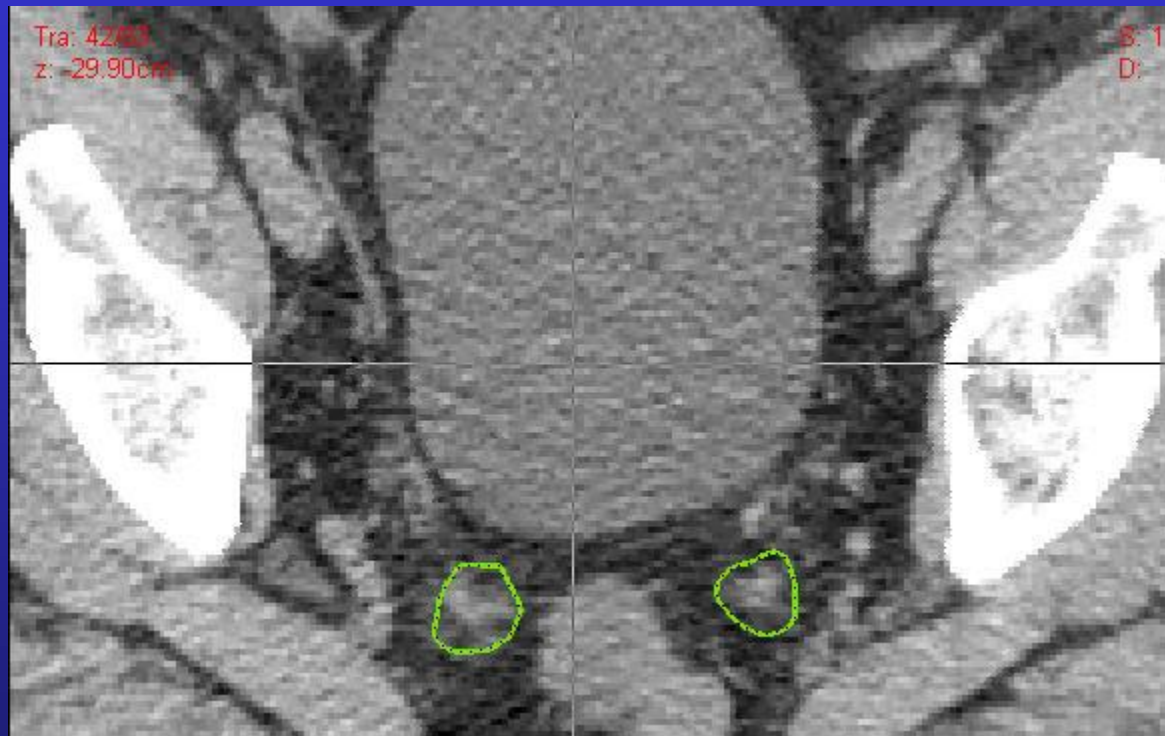Post Op Positive Seminal Vesicle

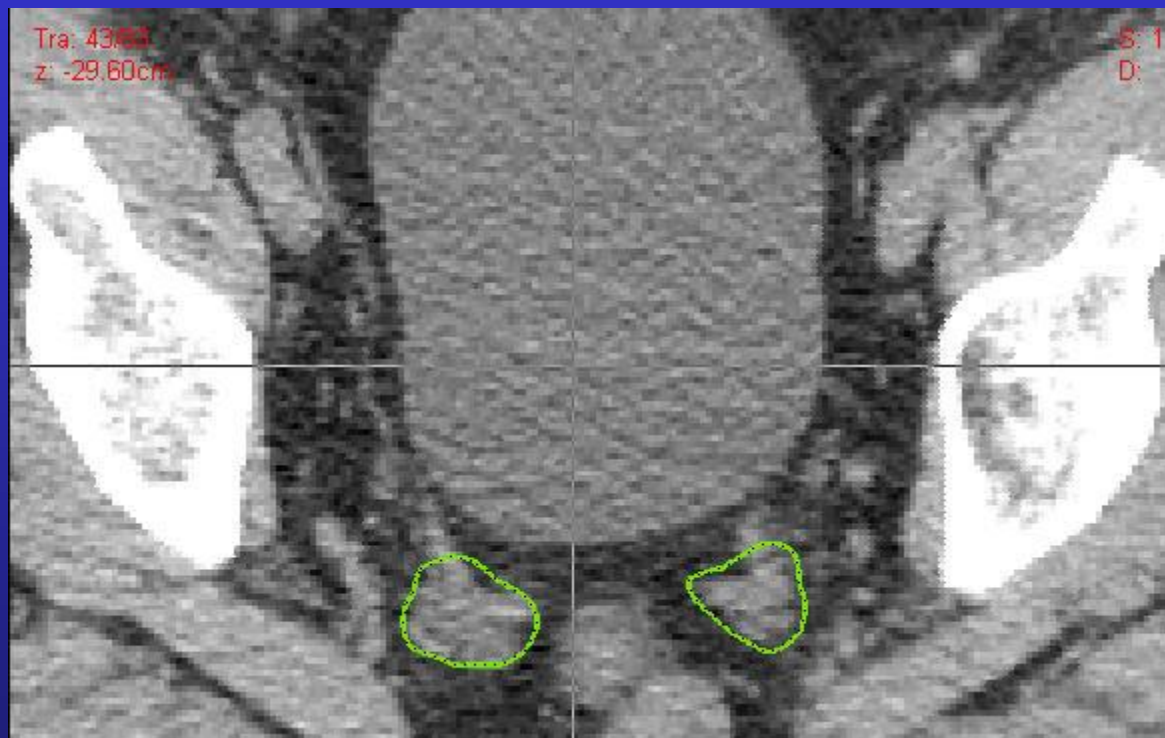
Case 4: Prostate_4

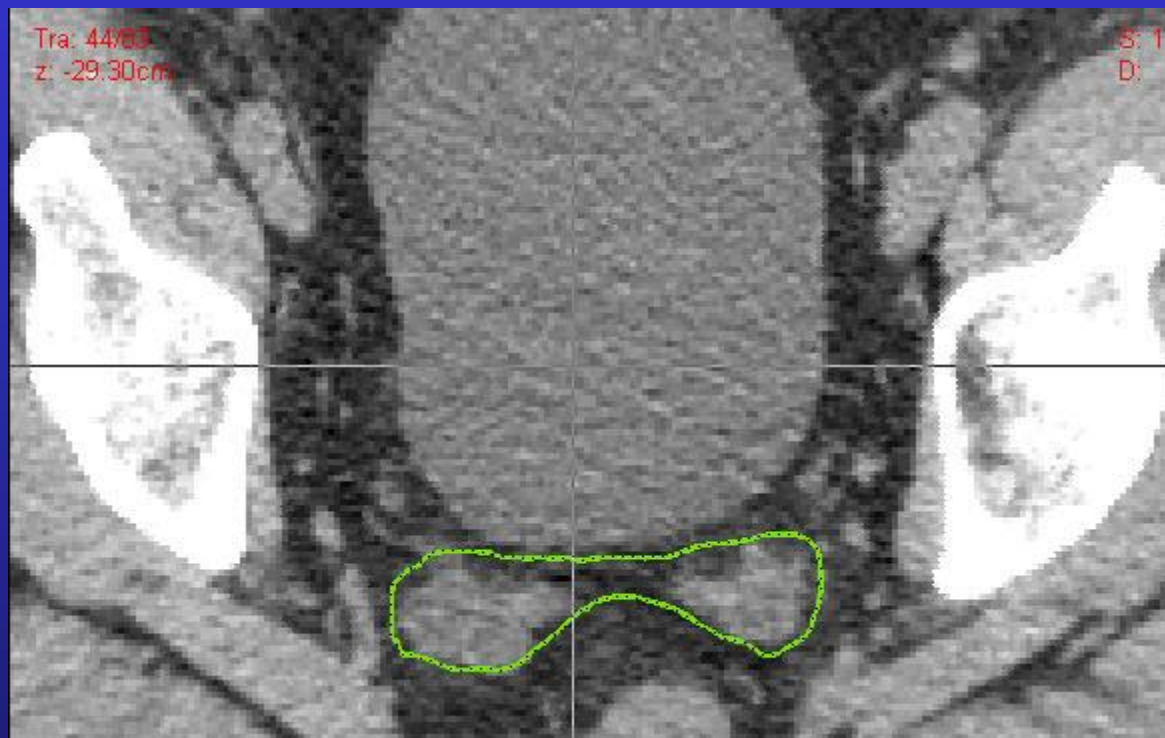
- Case 4
- A 68-year-old gentleman with a preop clinical T2a, Gleason 8 (4+4) PSA 15 adenocarcinoma of the prostate. He is status post radical retro pubic prostatectomy and found to have pathologic T3b, pN0 (12 lymph nodes taken – all negative) Gleason Scores 8 (4+4) disease. Pathology reveals extracapsular extension at the right base and right seminal vesicle invasion. Surgical margins are negative. His PSA is undetectable and he is referred to you 90 days postop. He has recovered urinary continence but is now impotent. Please draw the CTV-TB for this case.

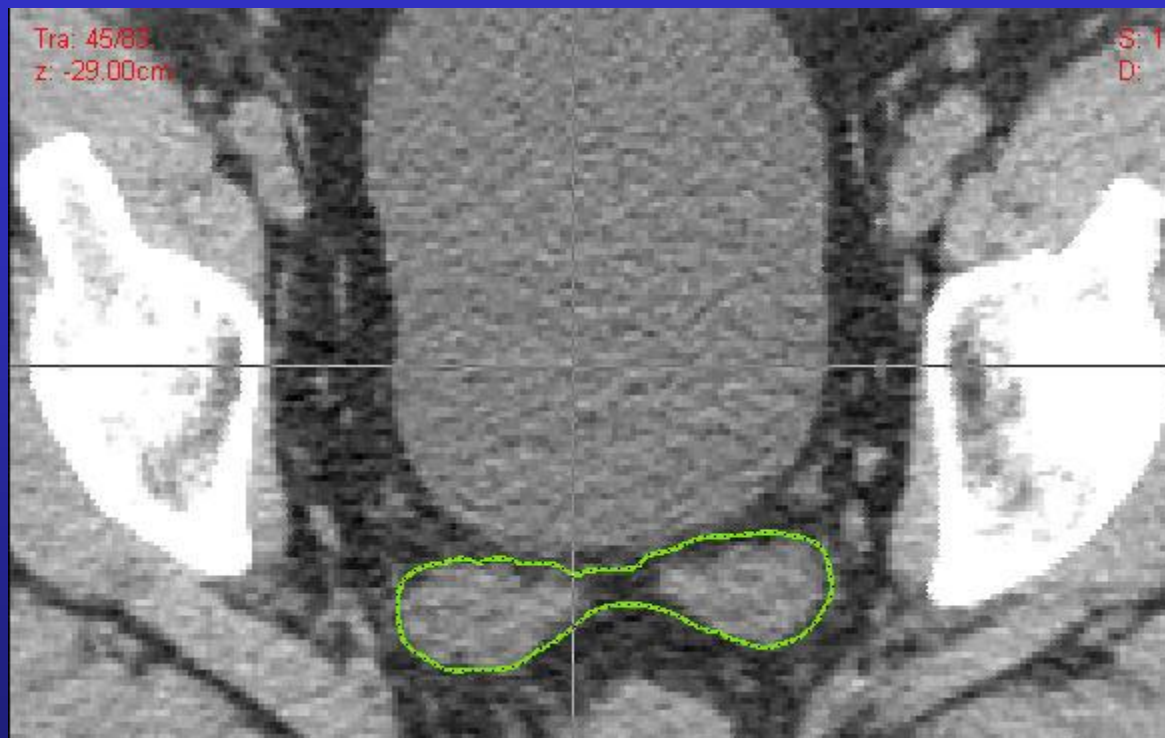


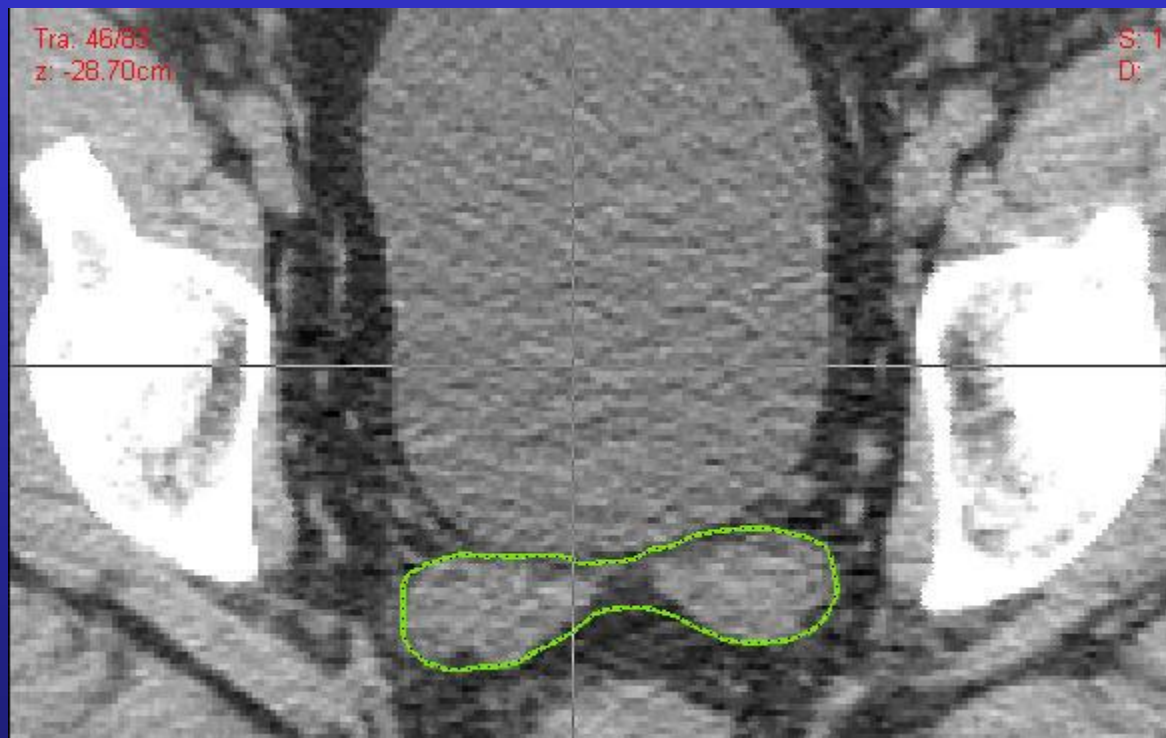


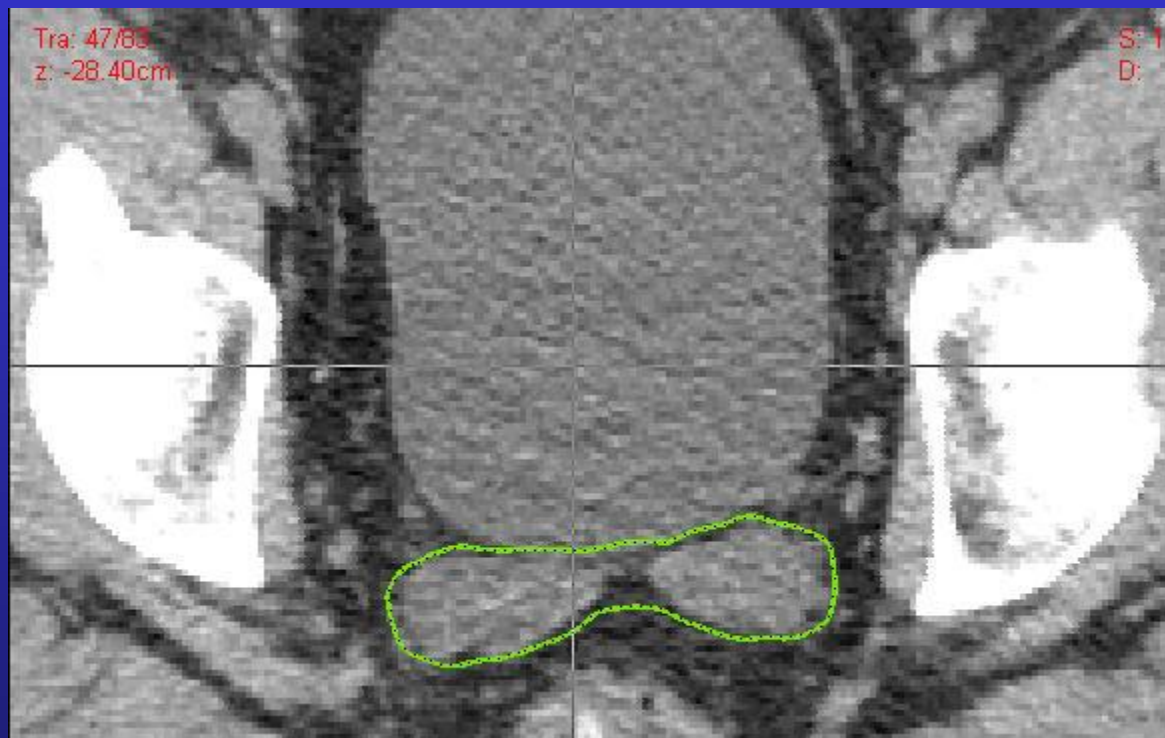


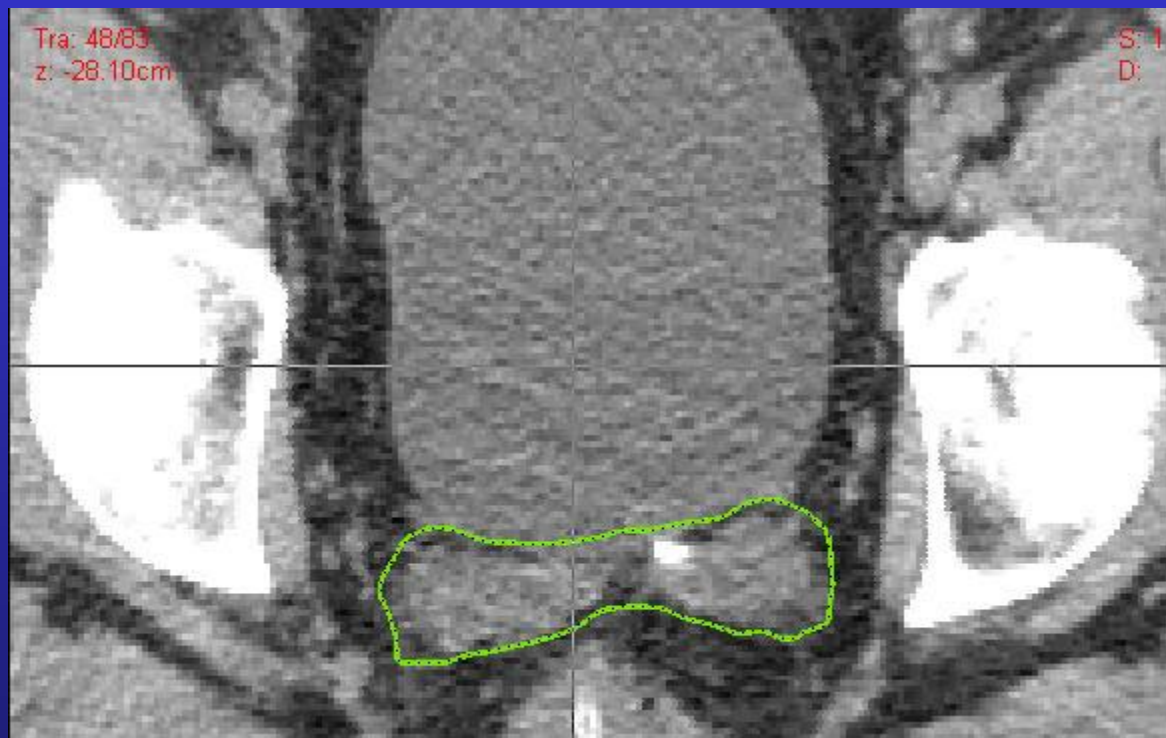


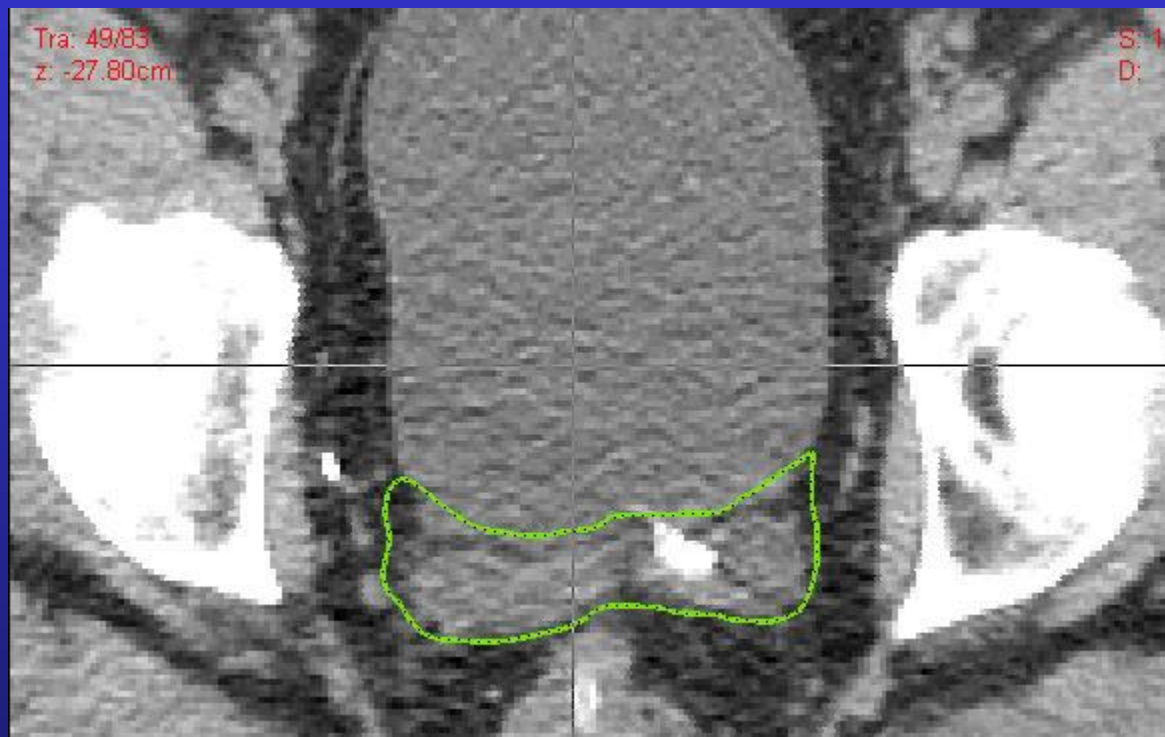


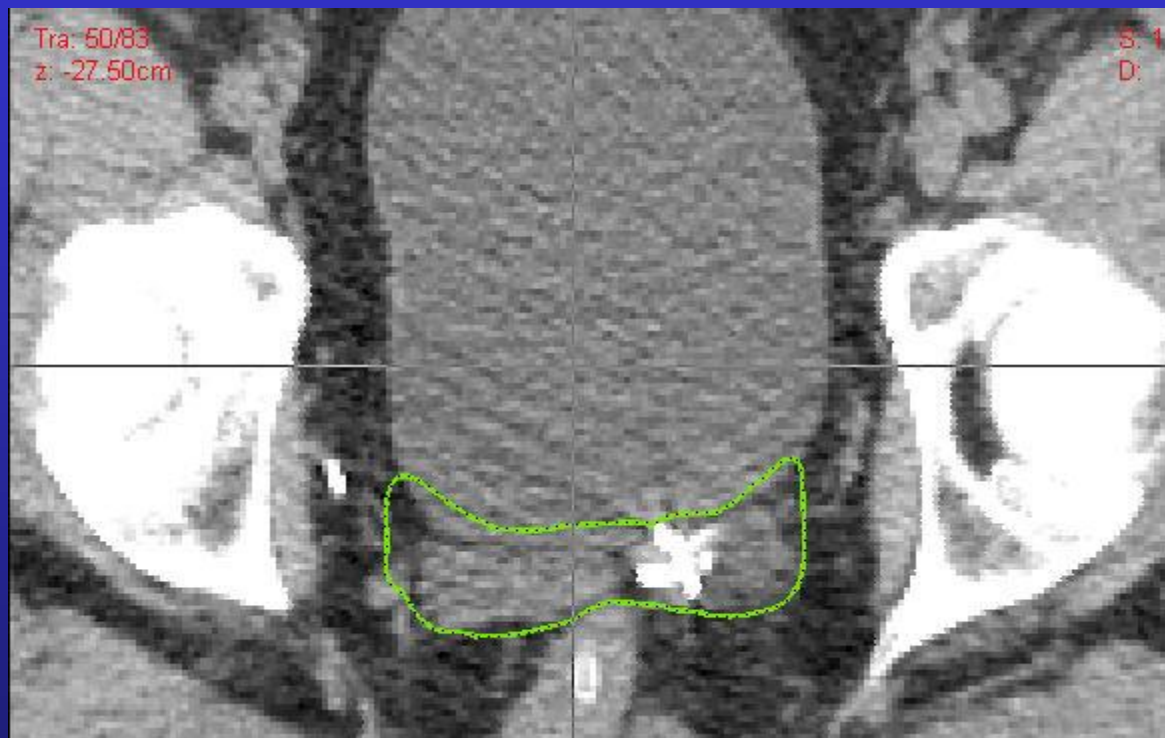


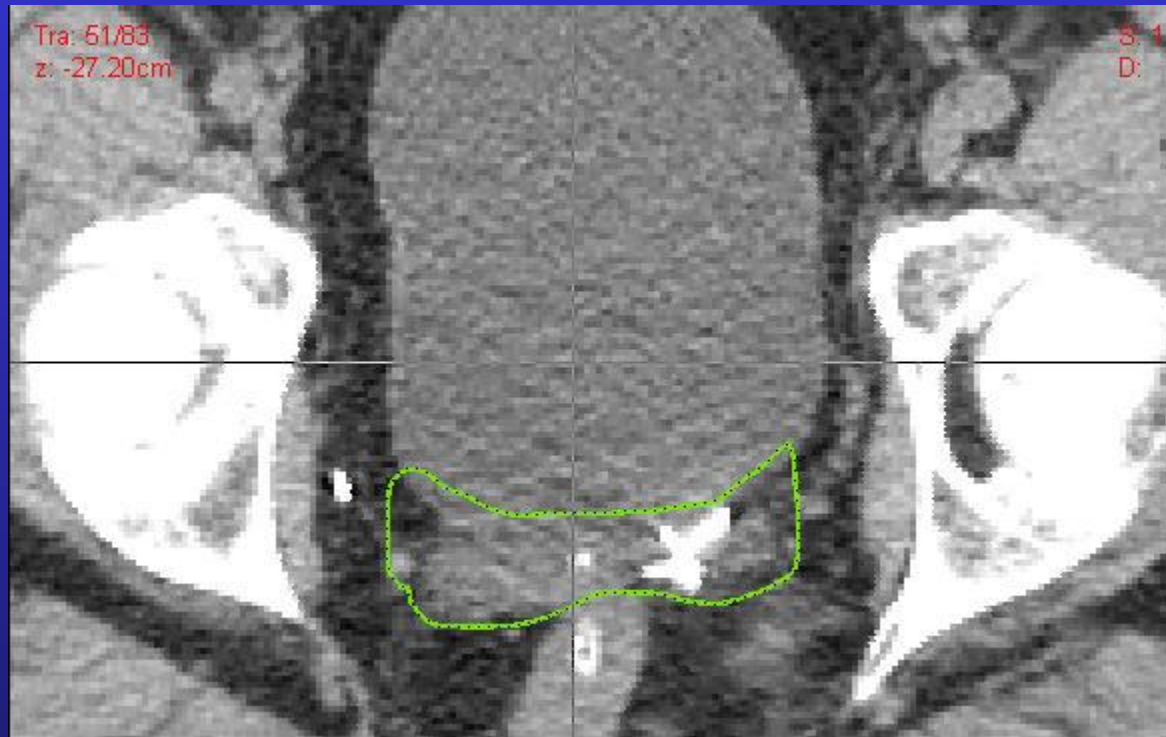


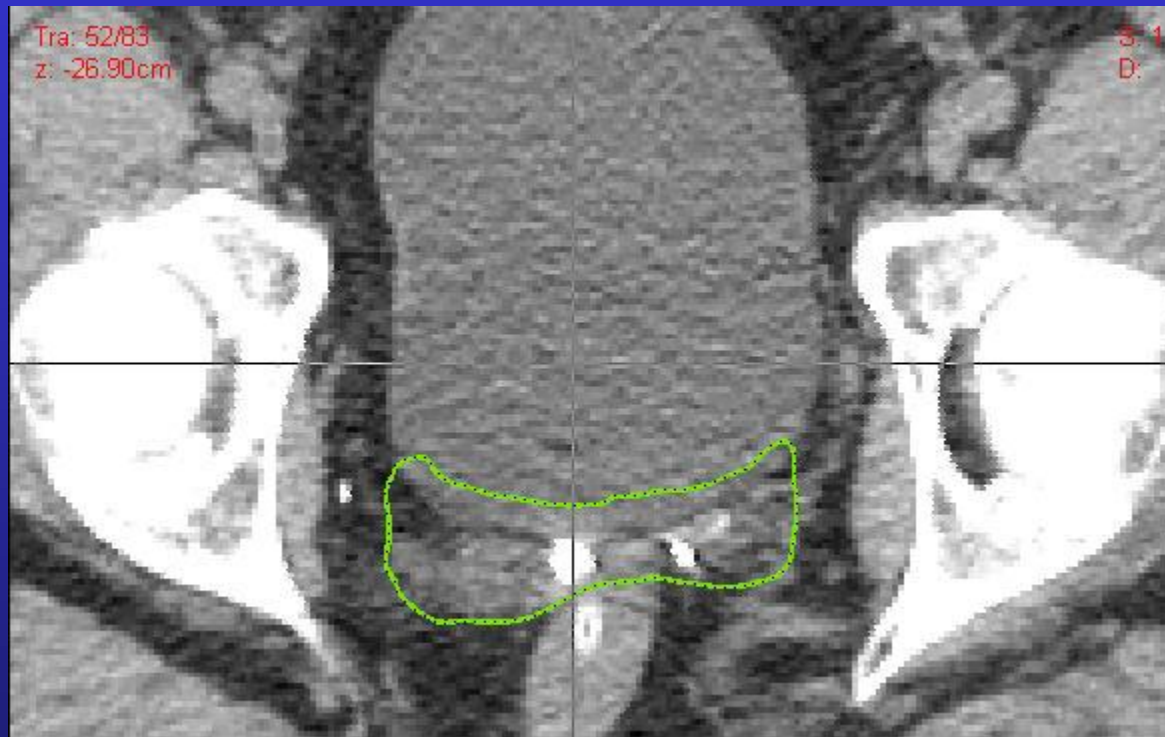


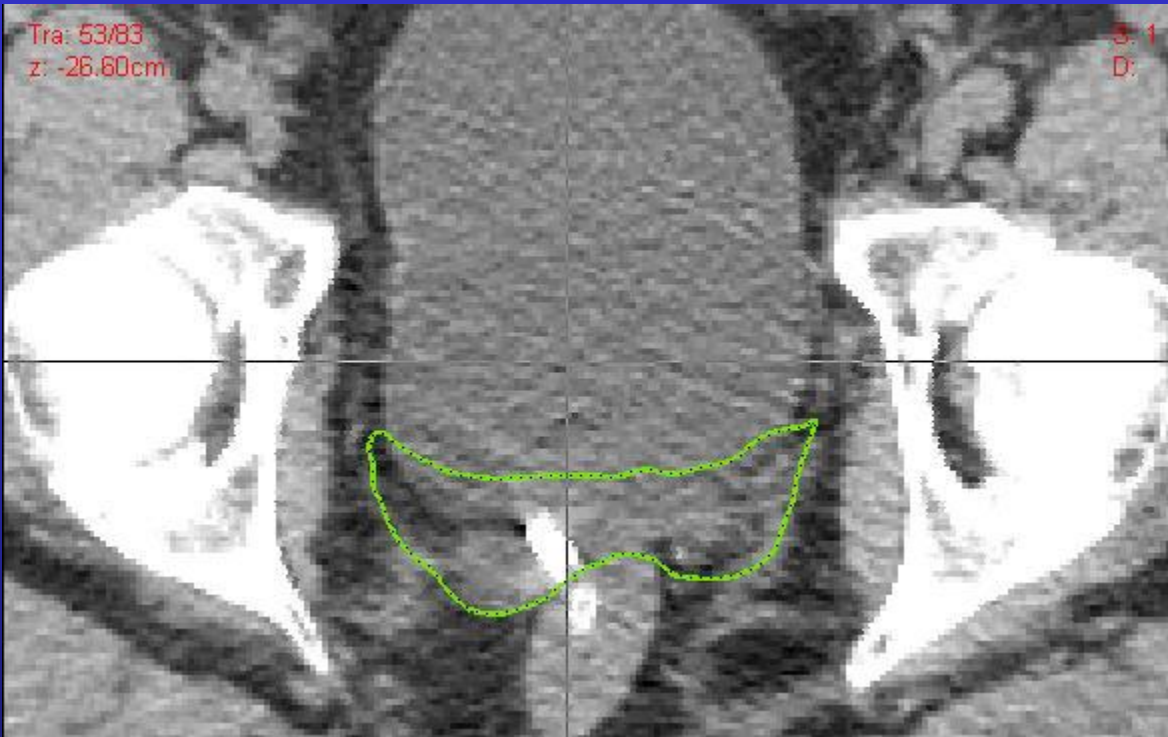


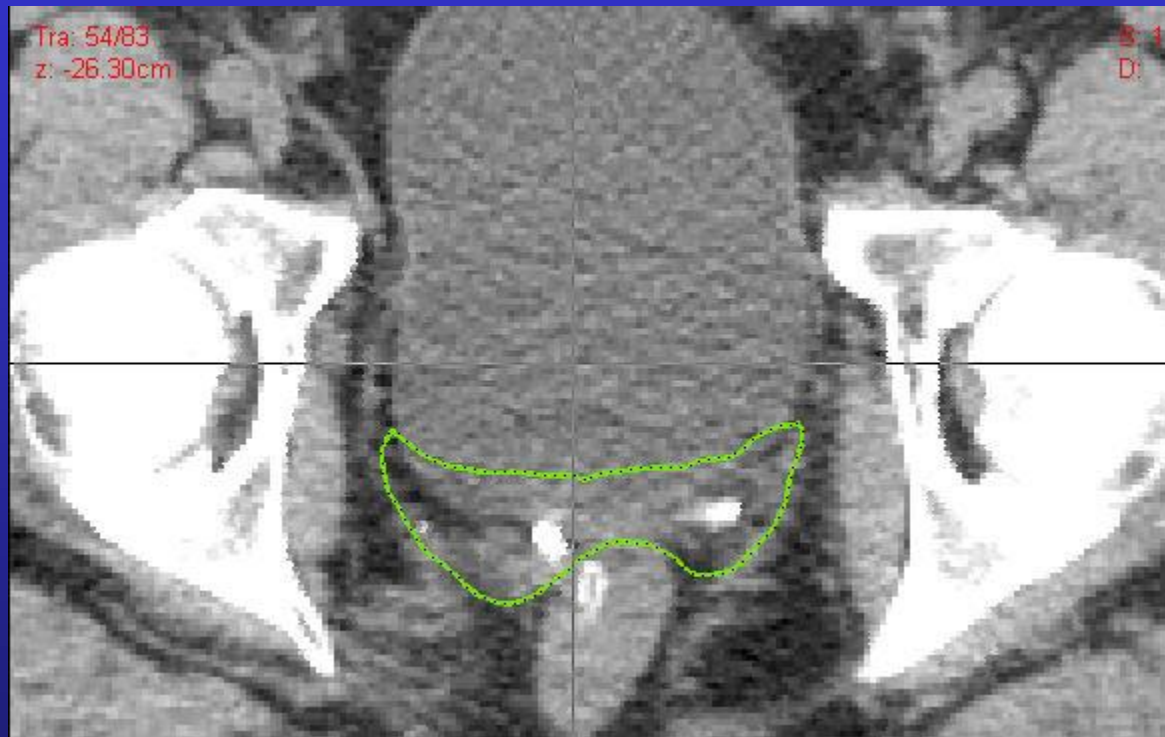


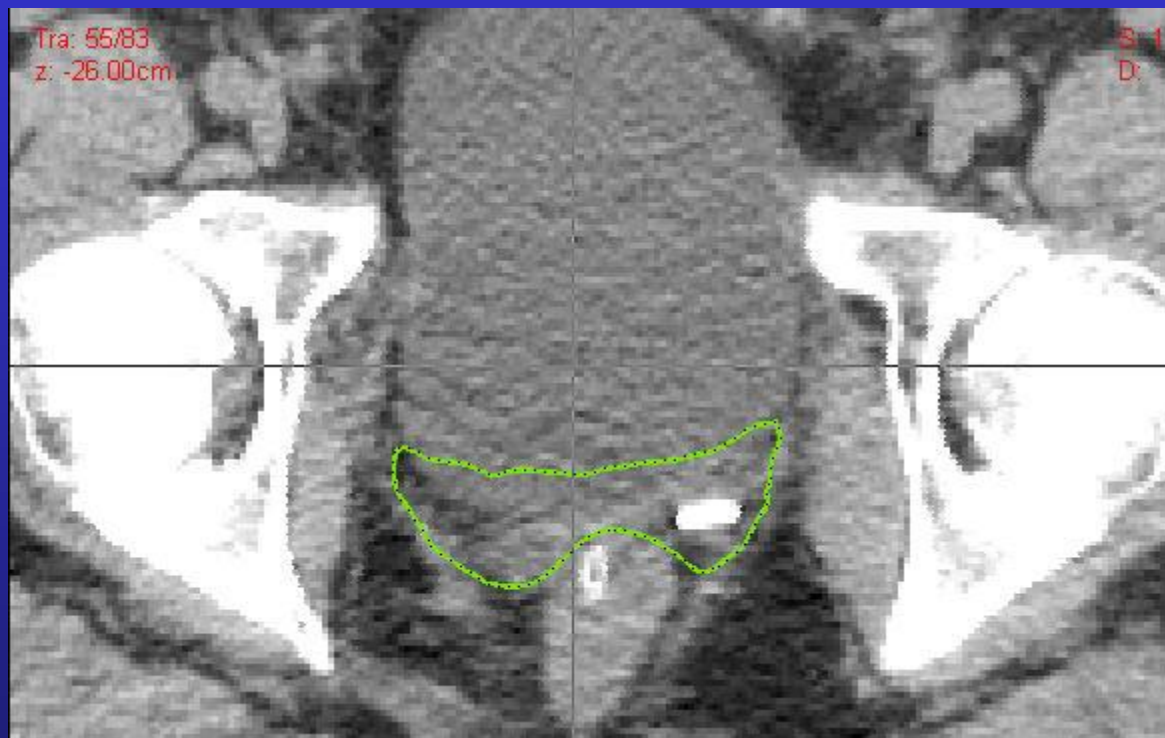

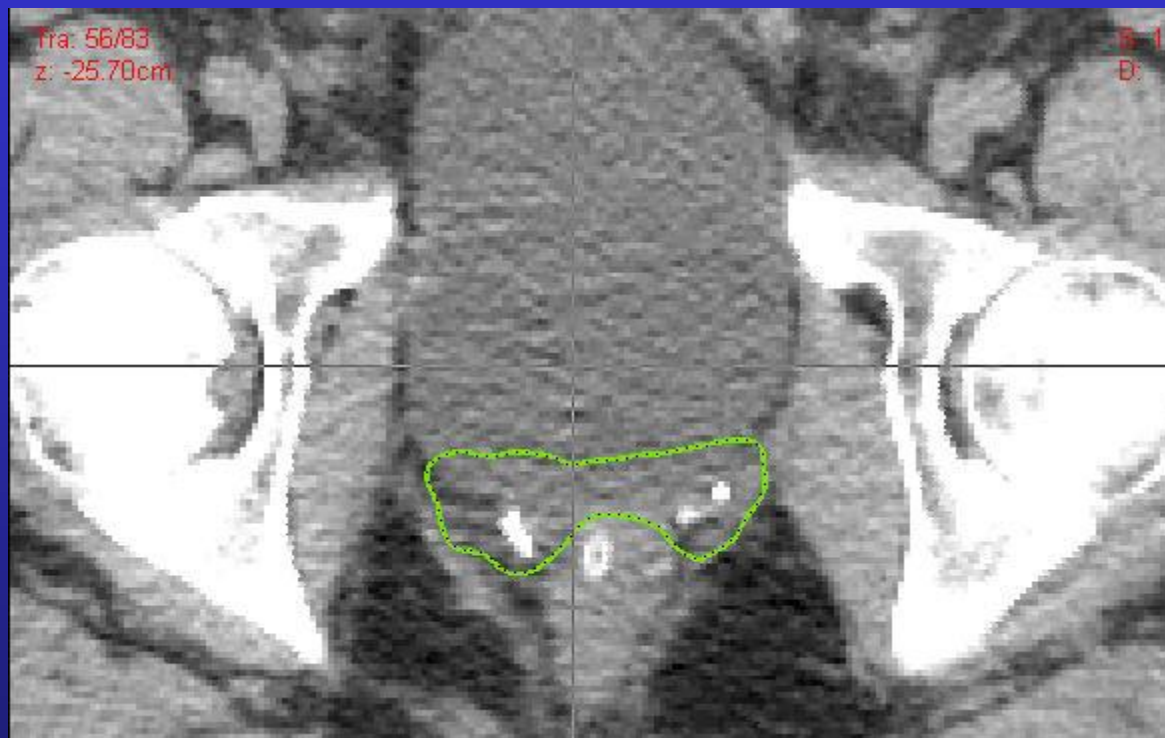


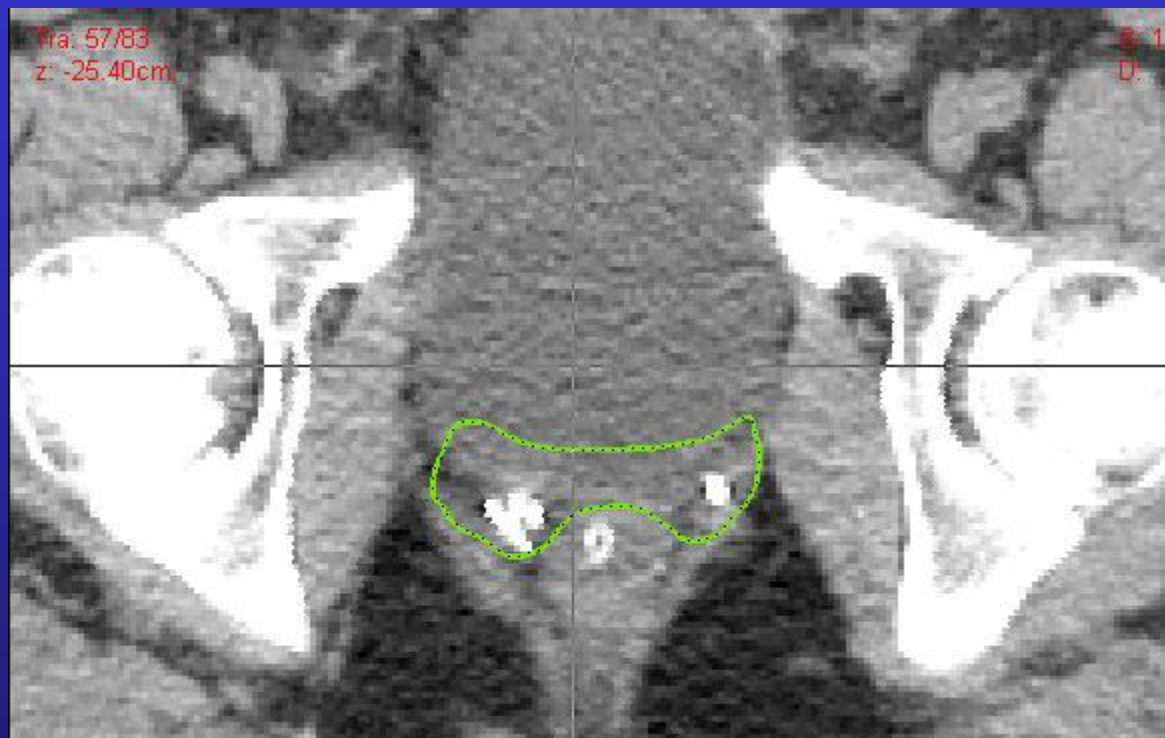



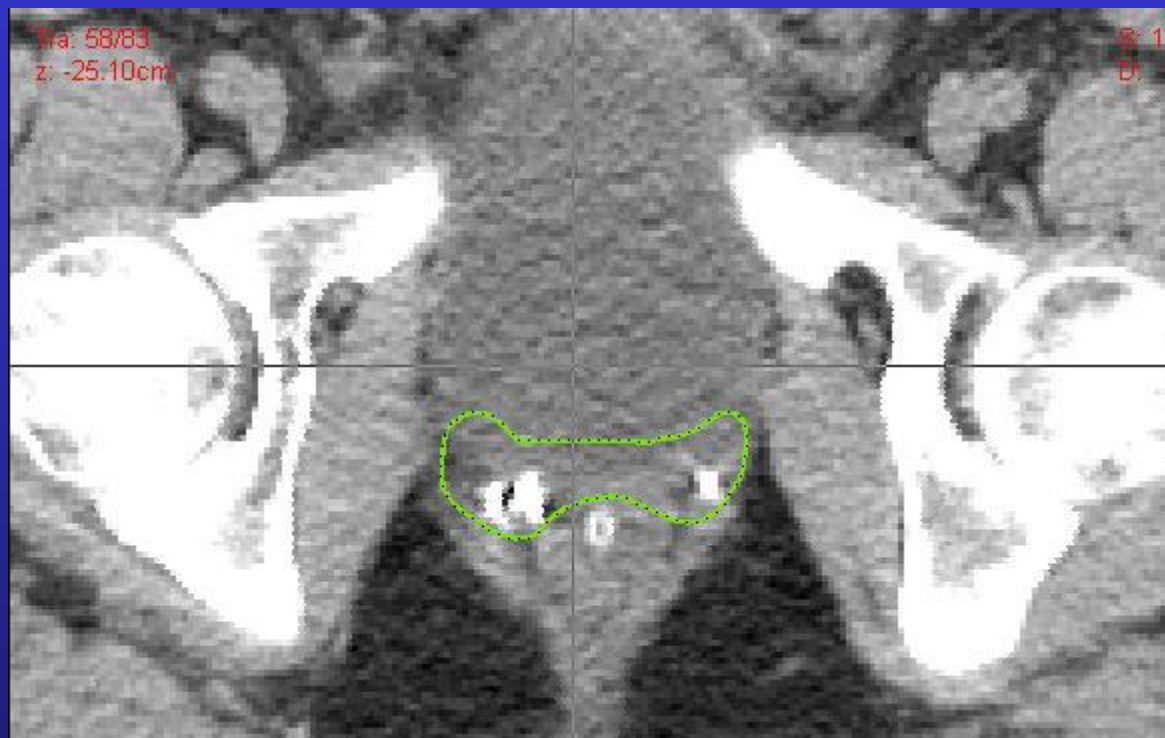


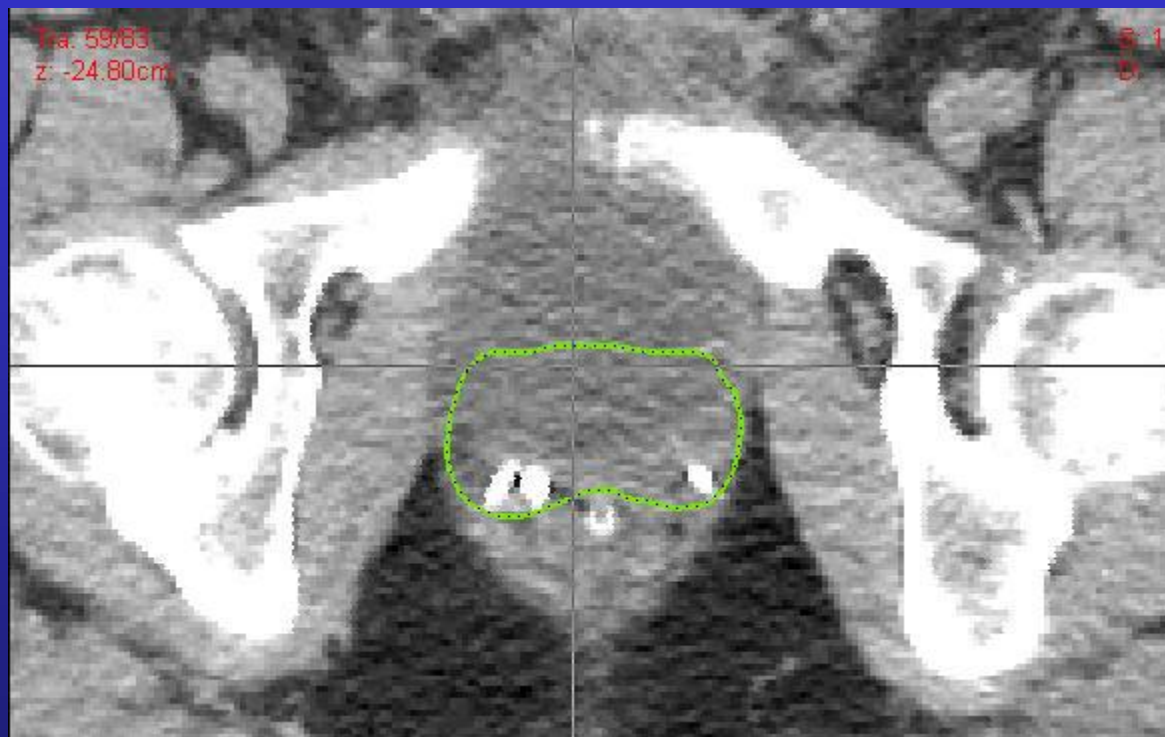


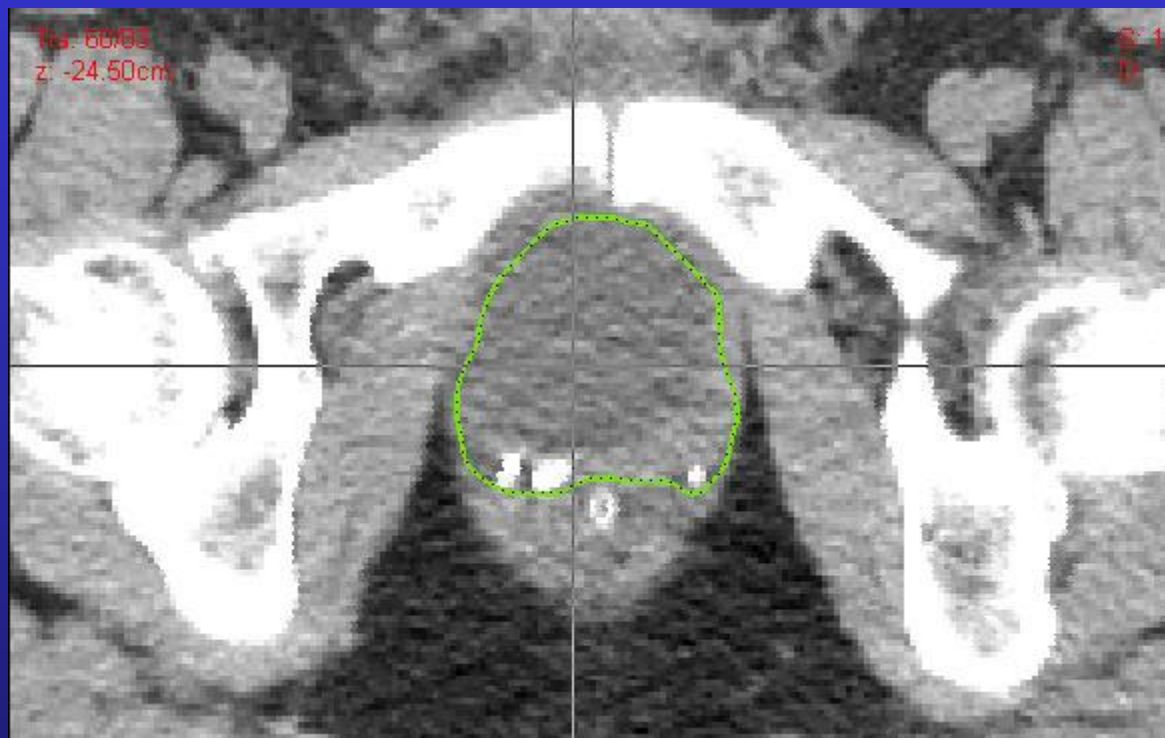


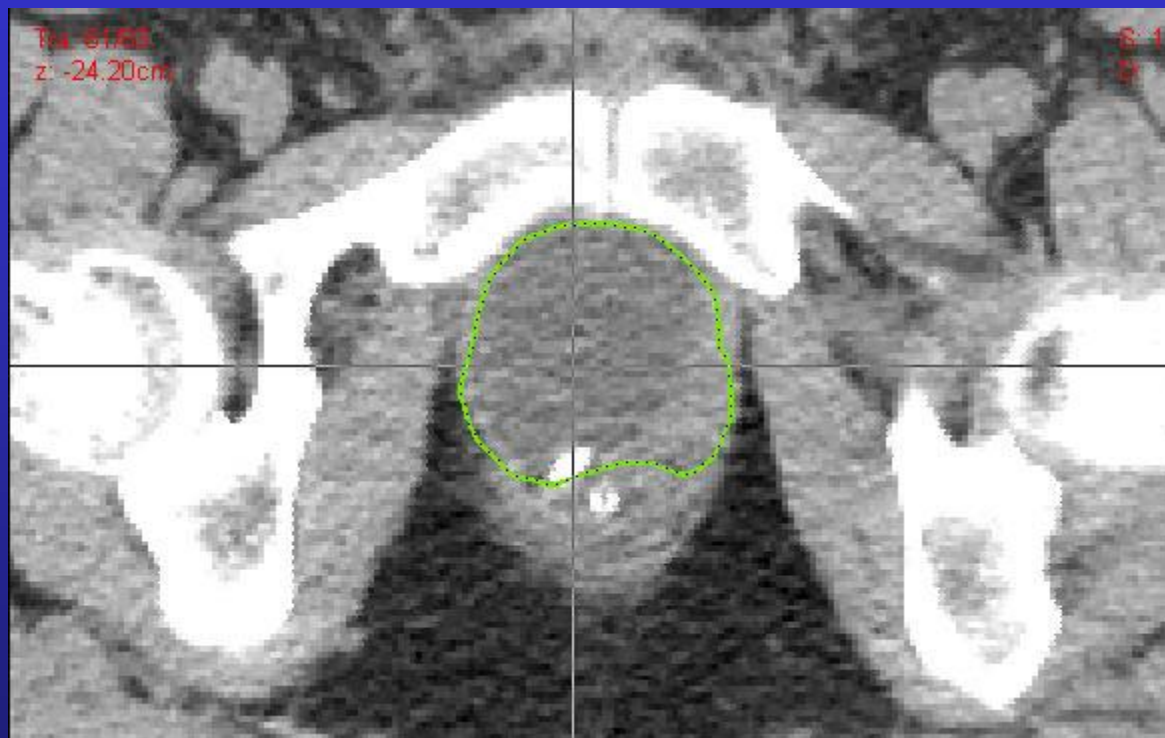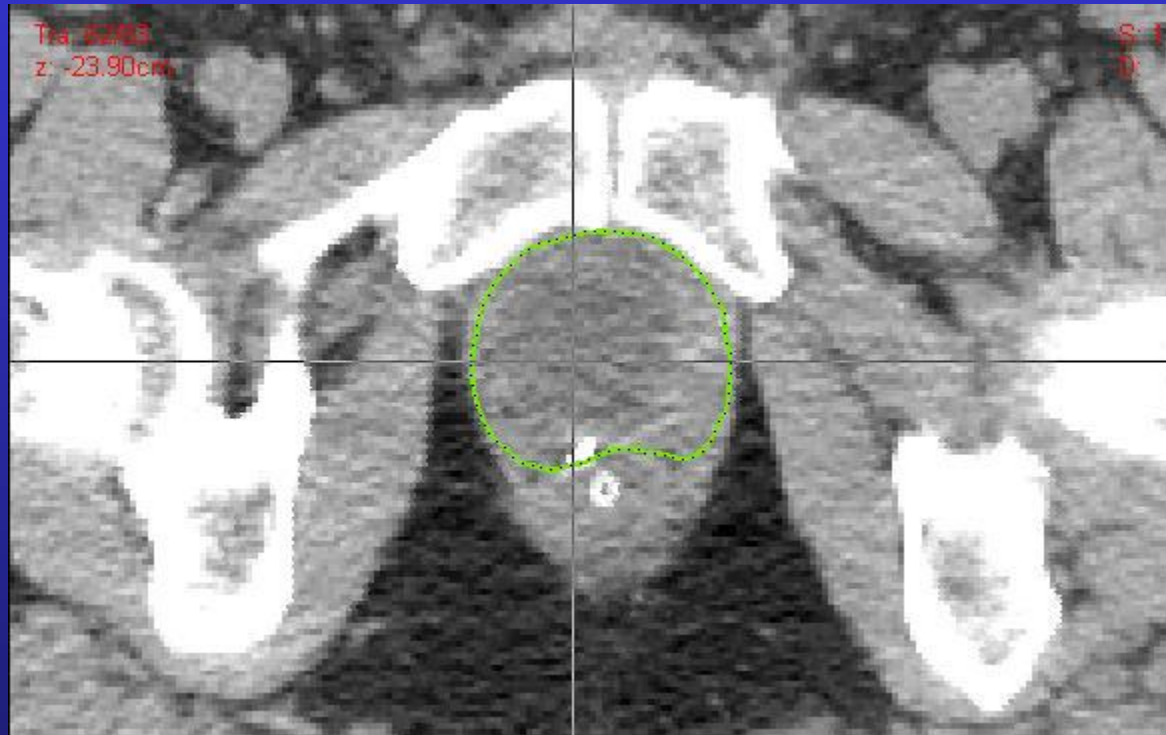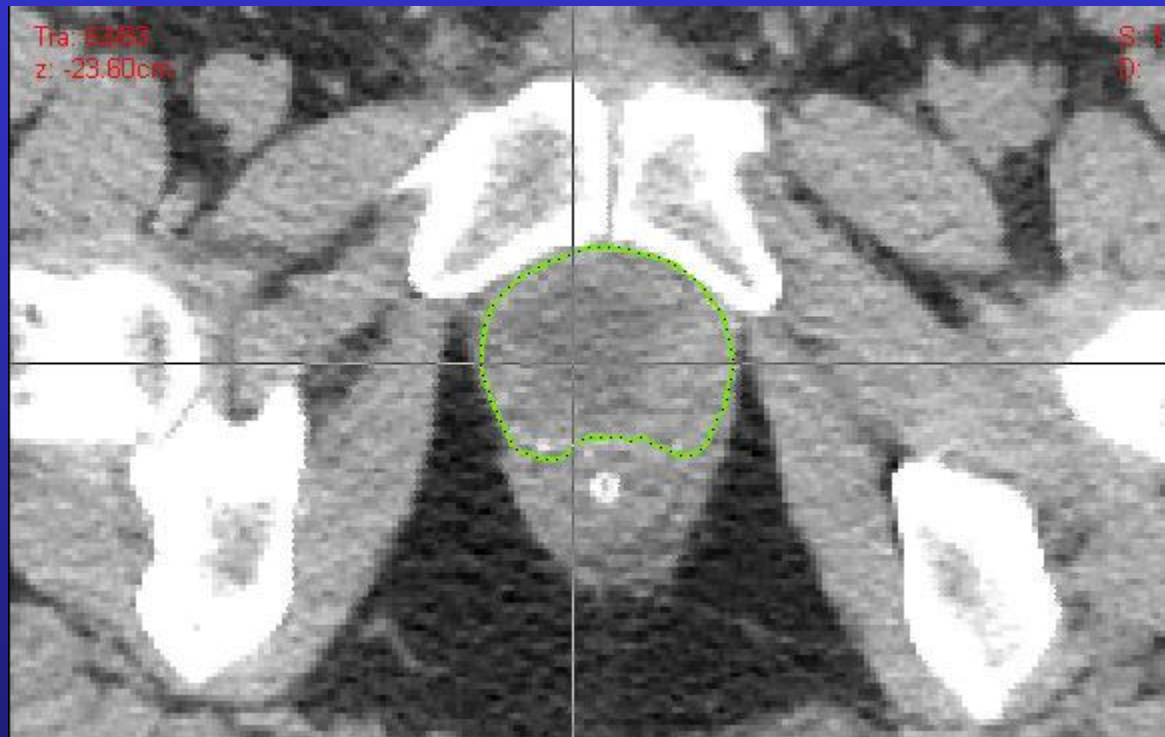


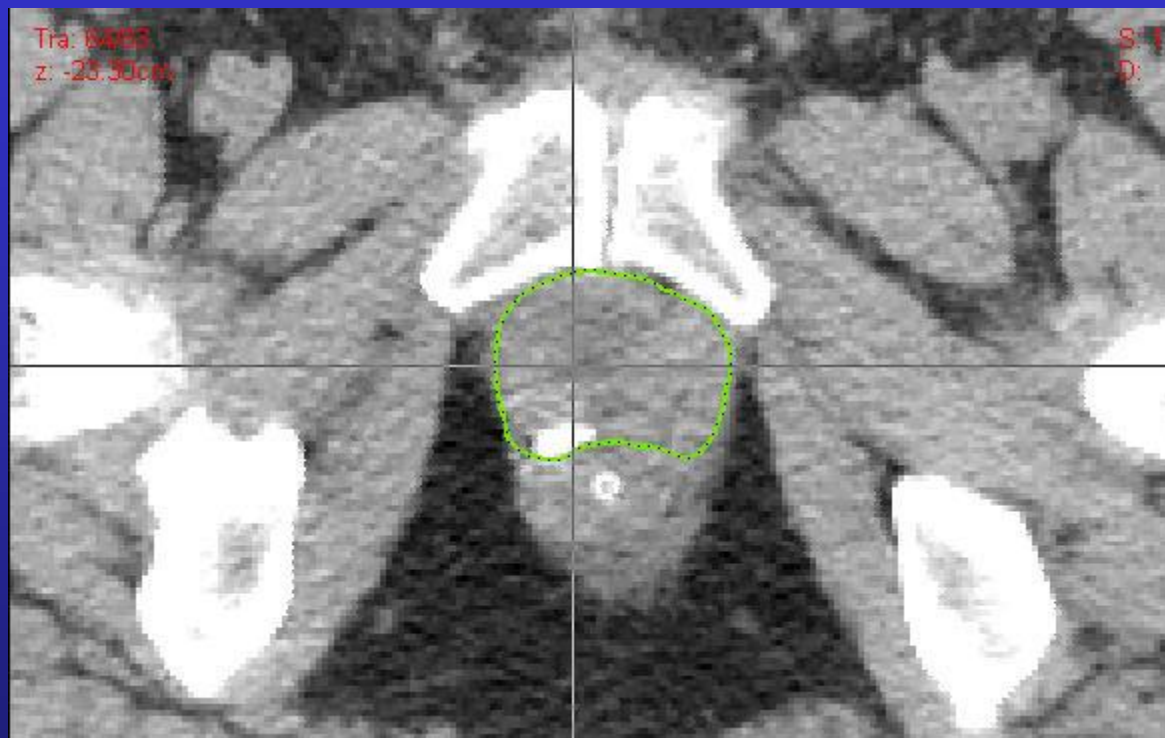








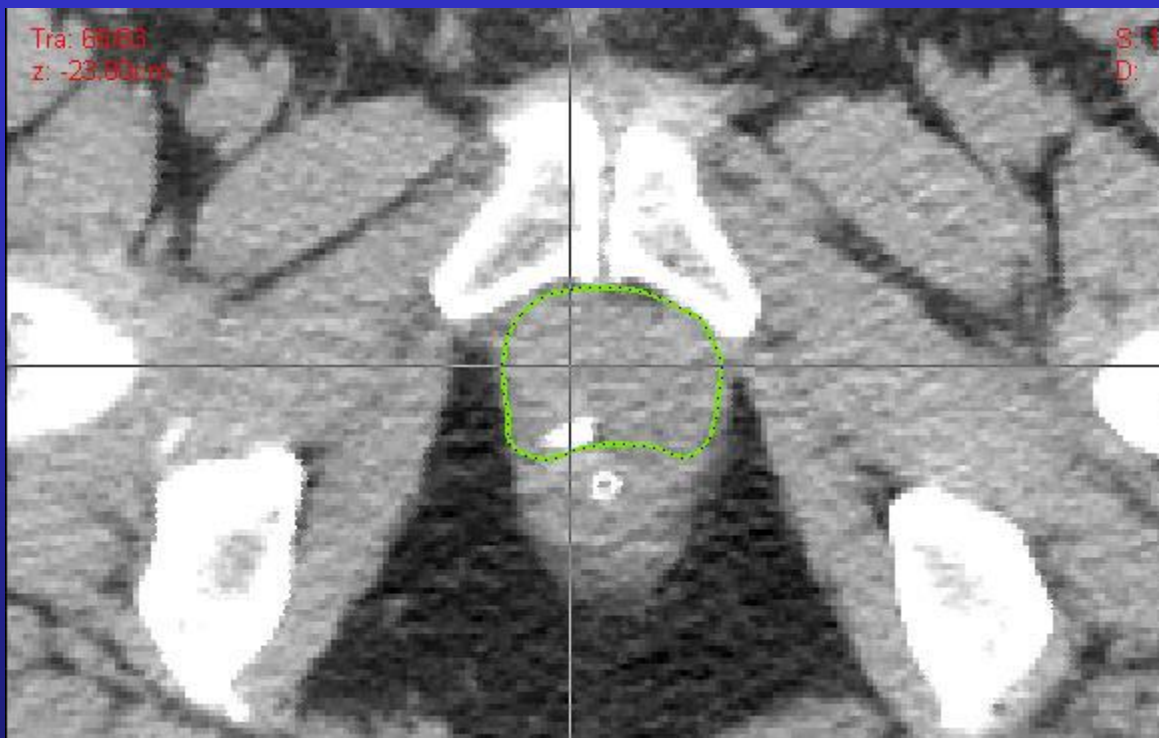

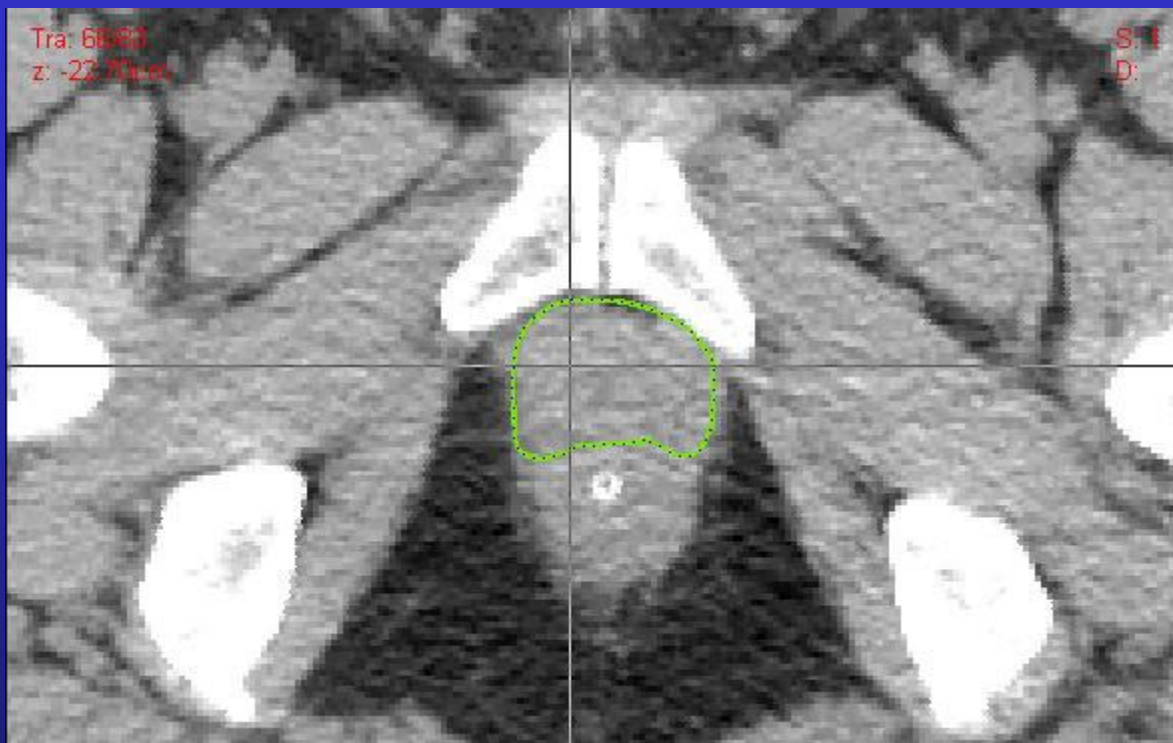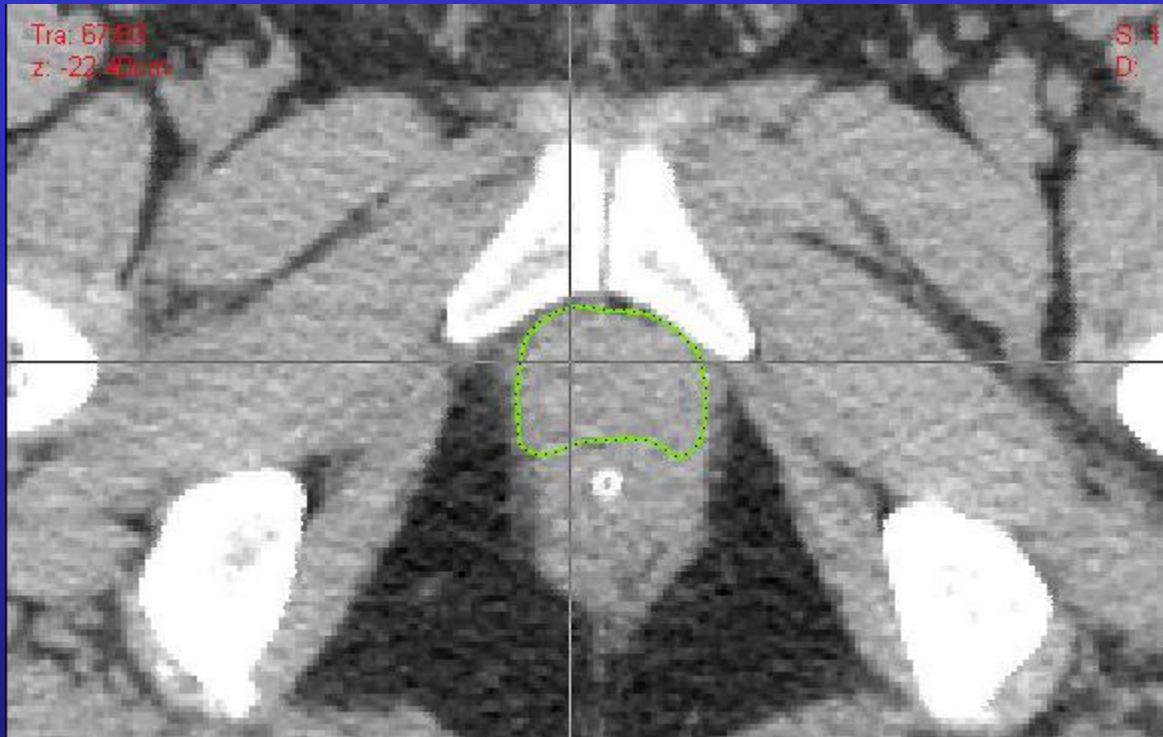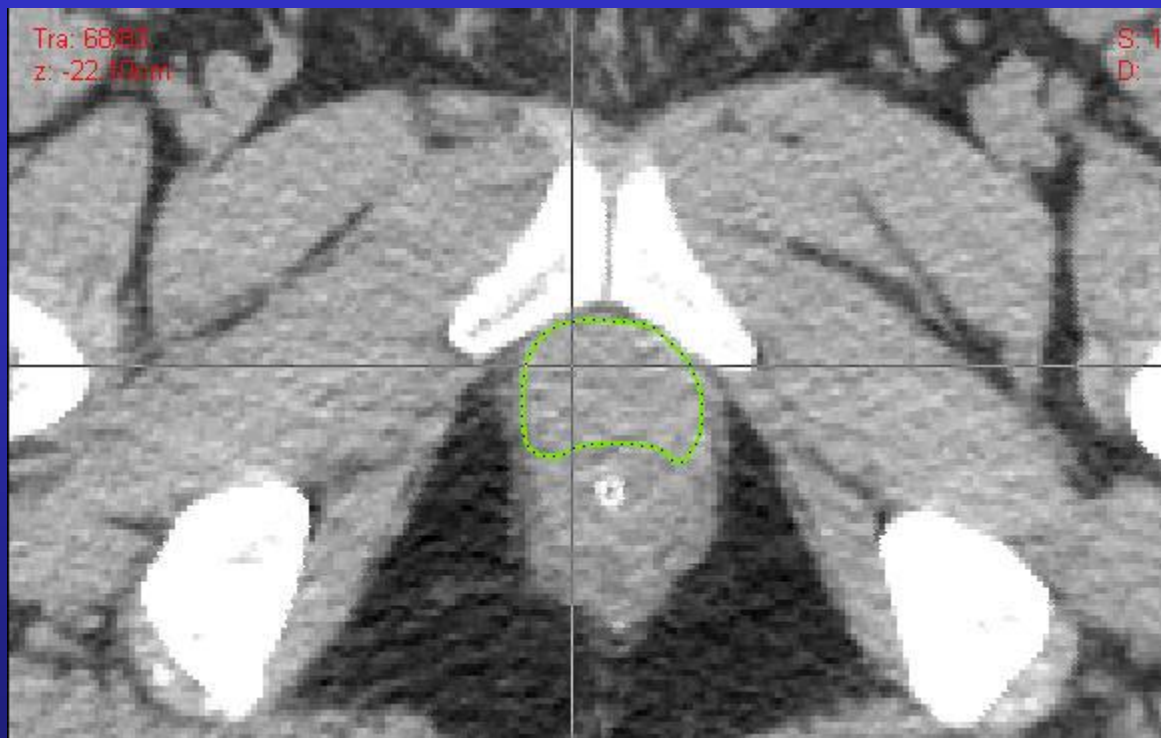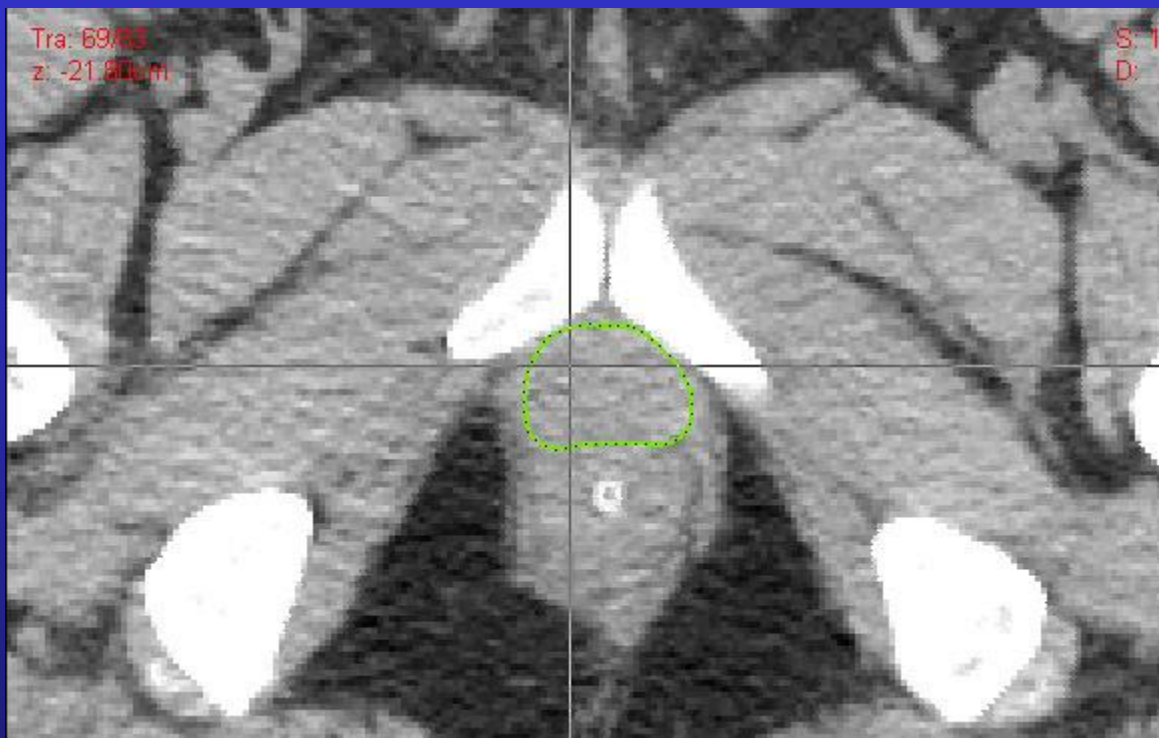








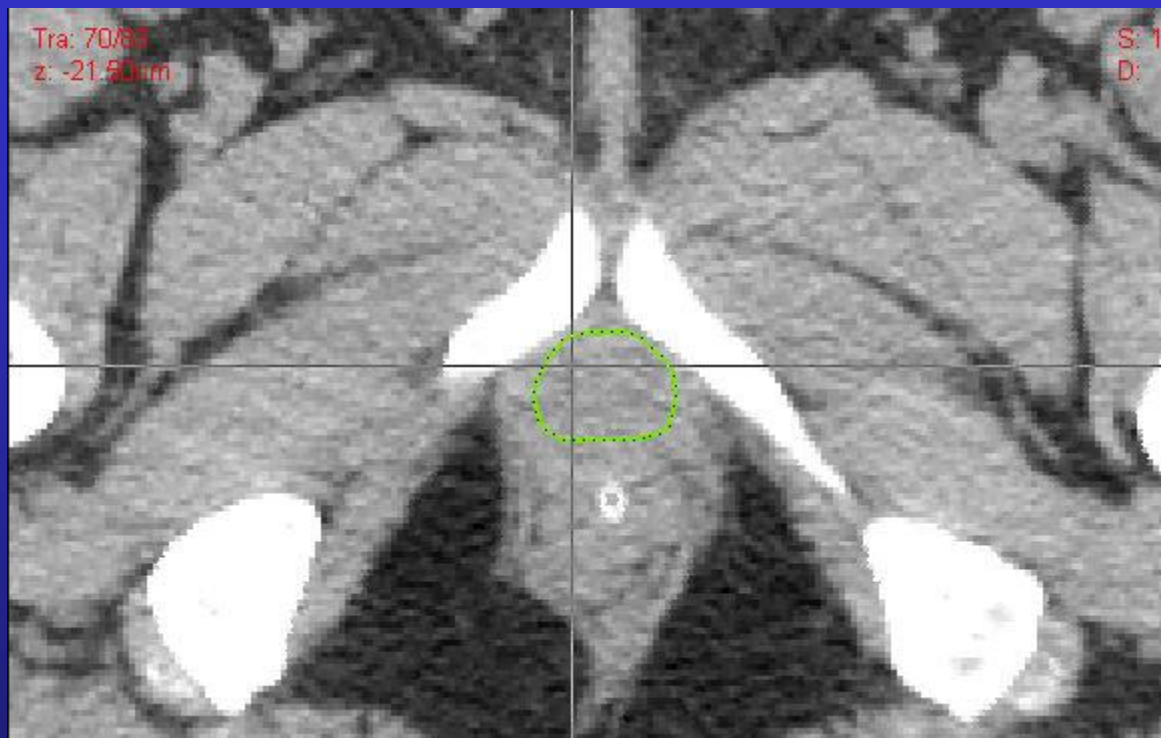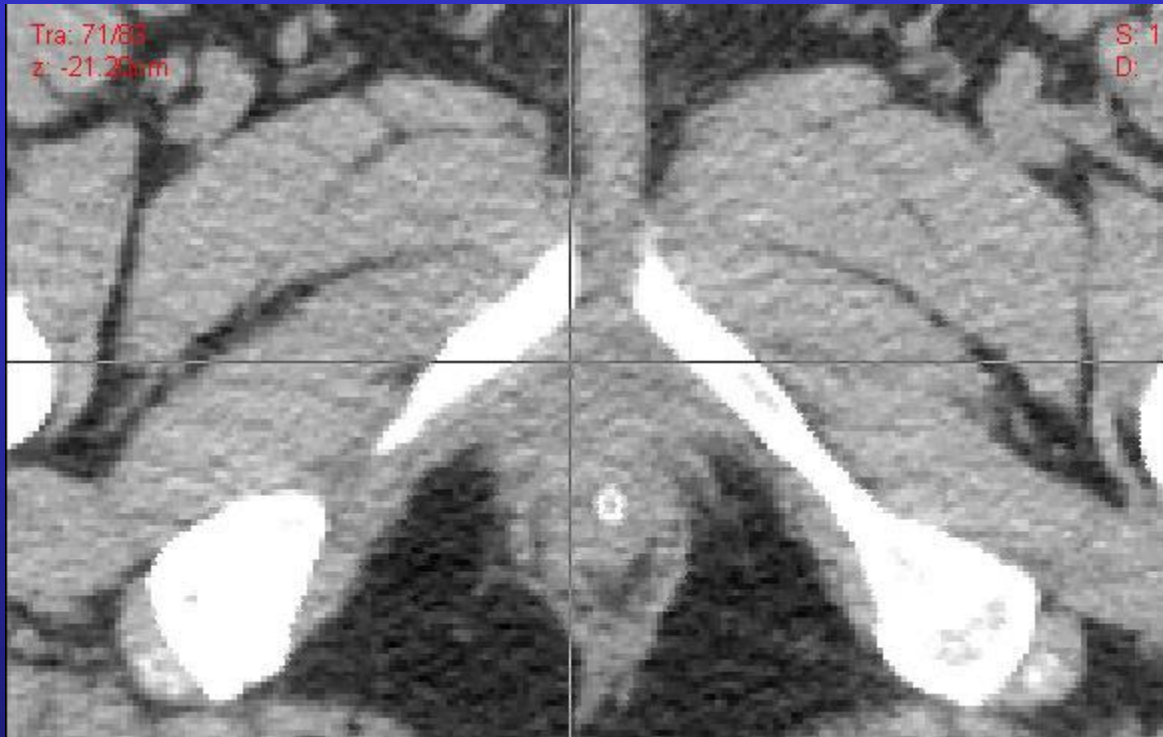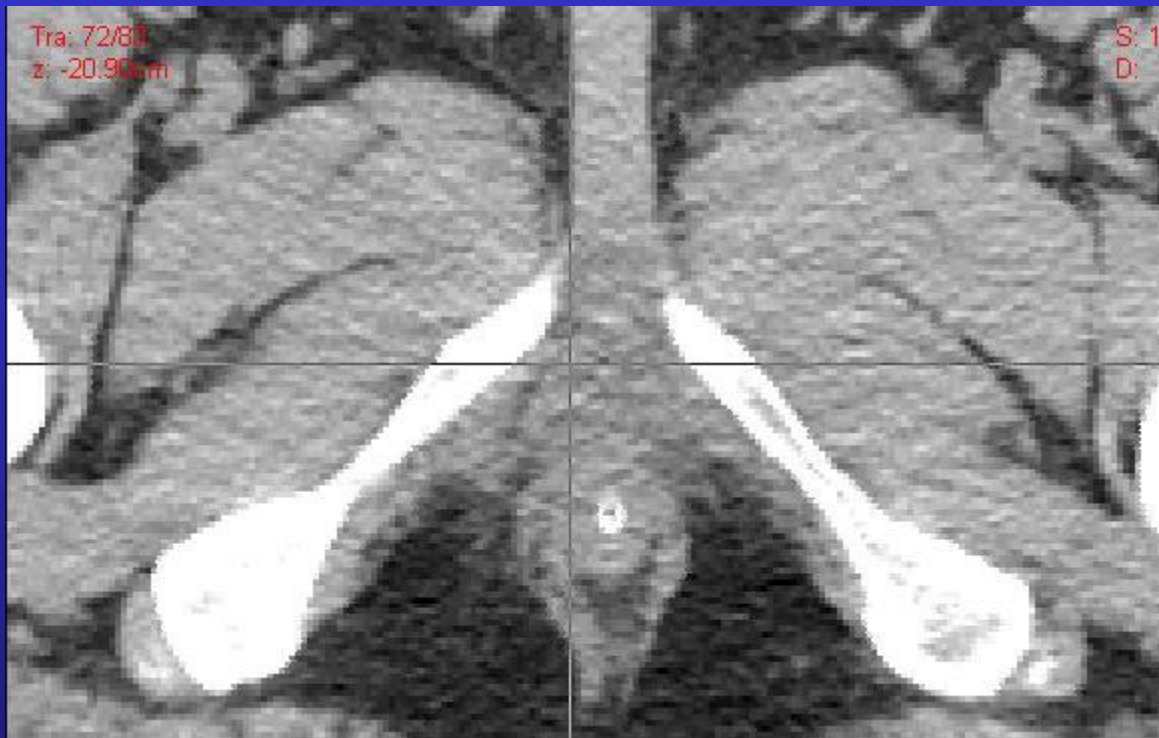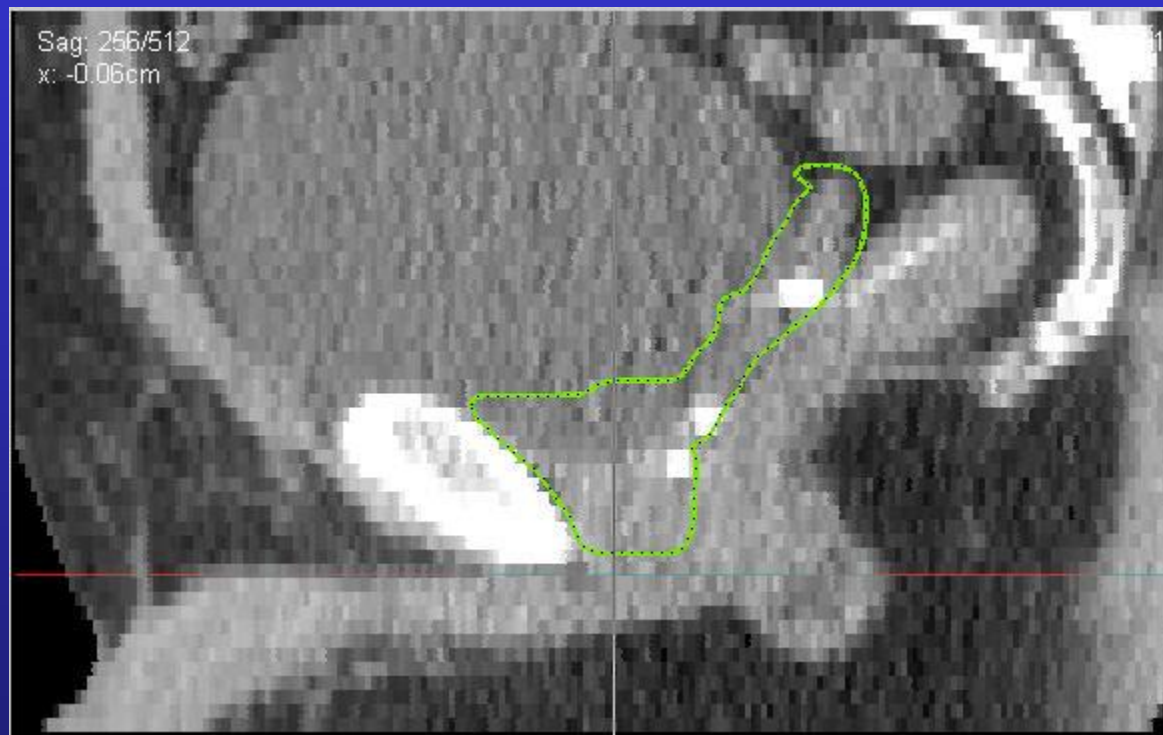


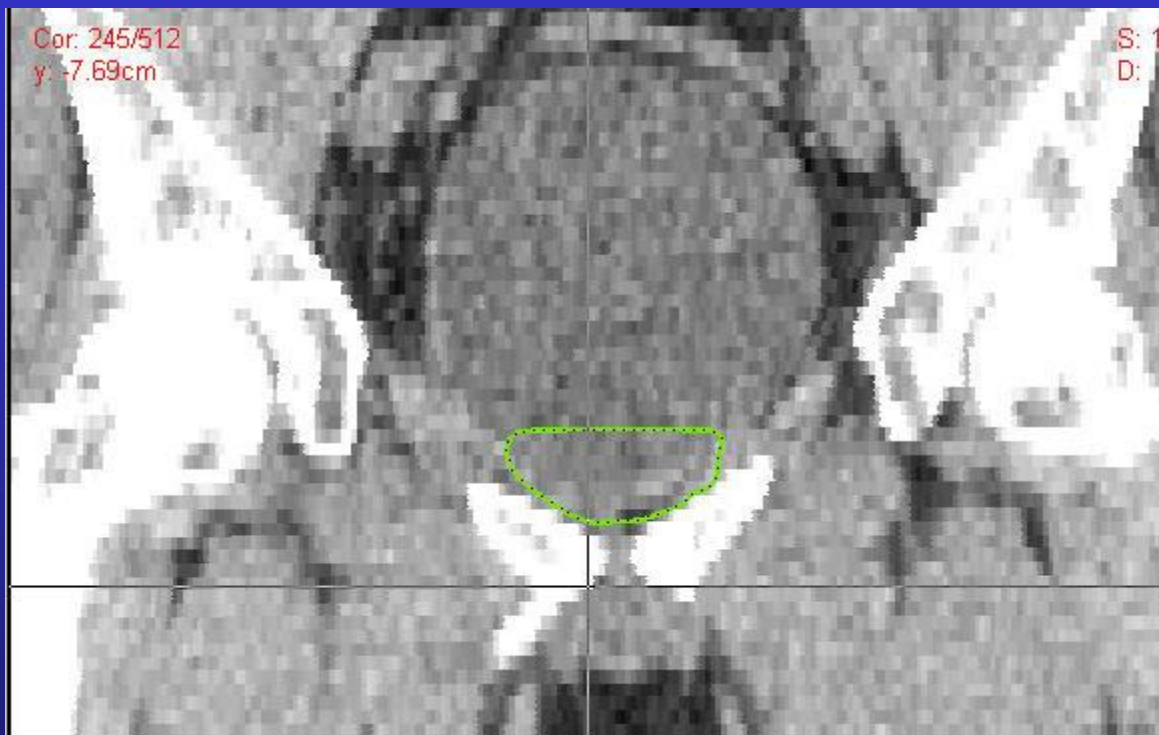




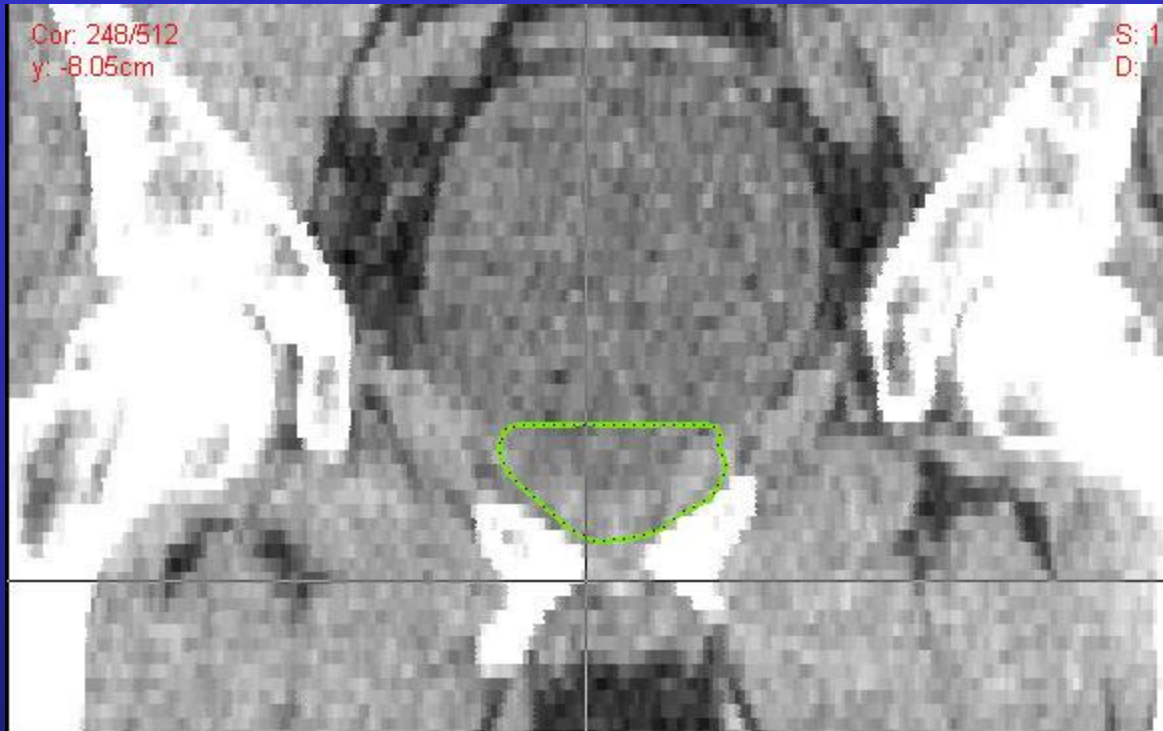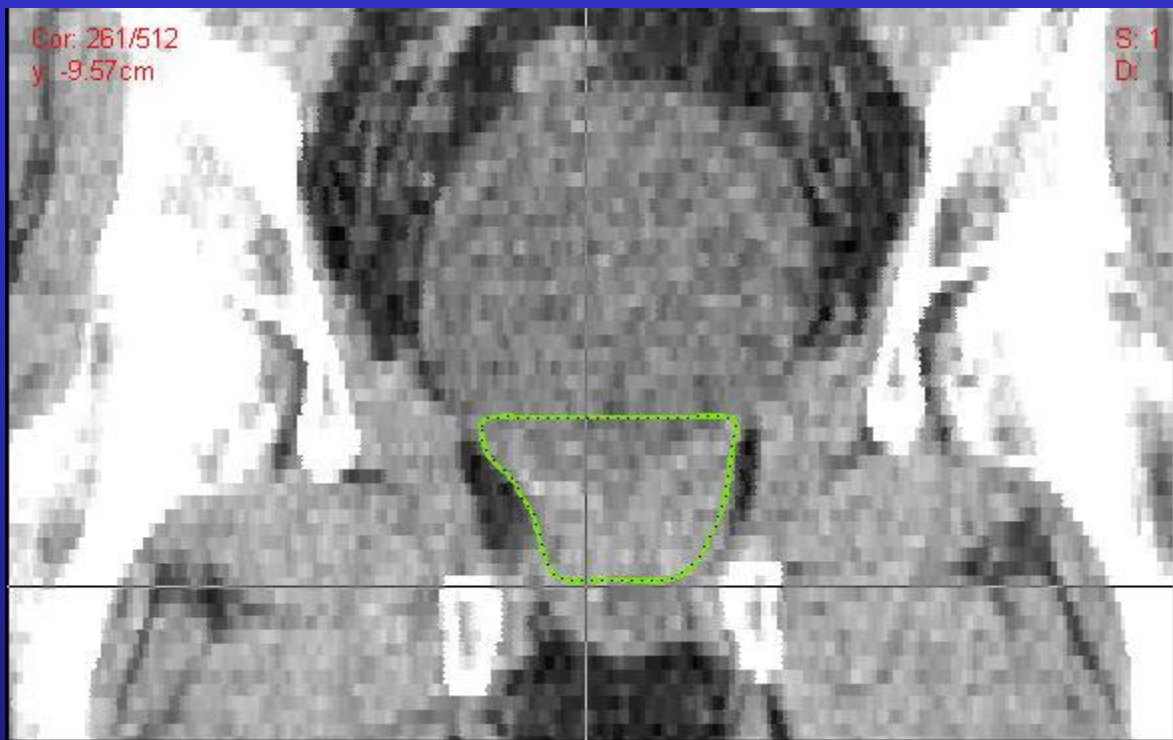


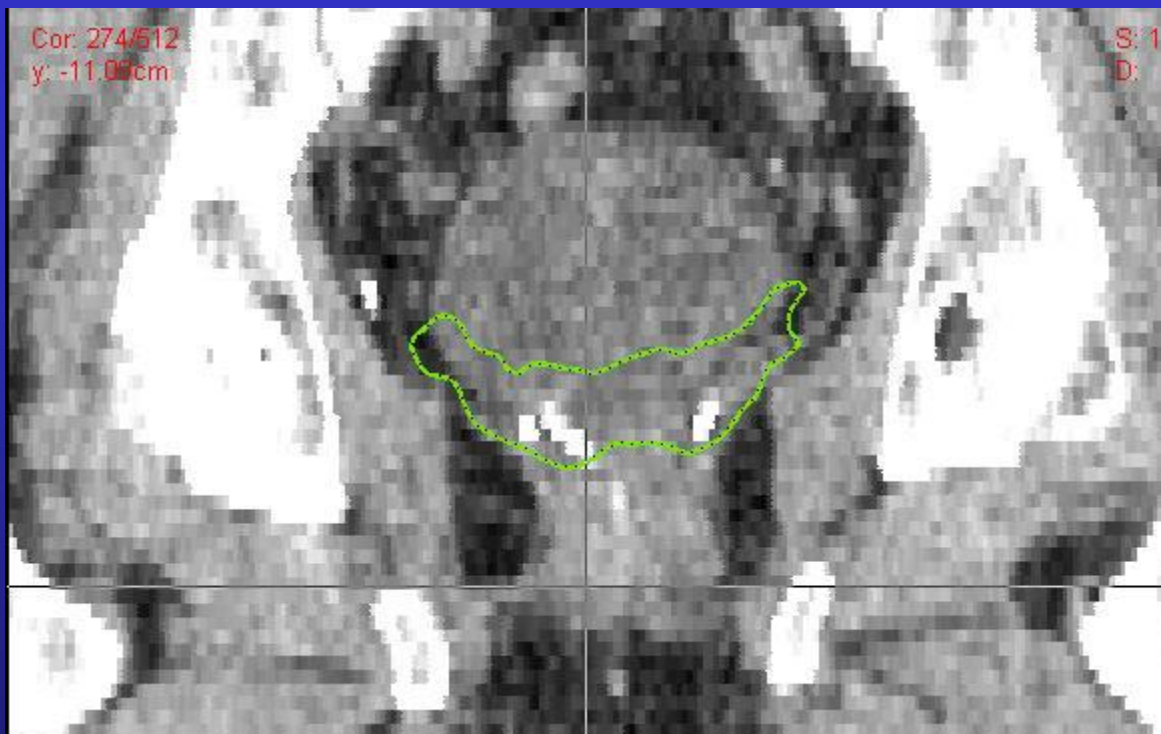












end