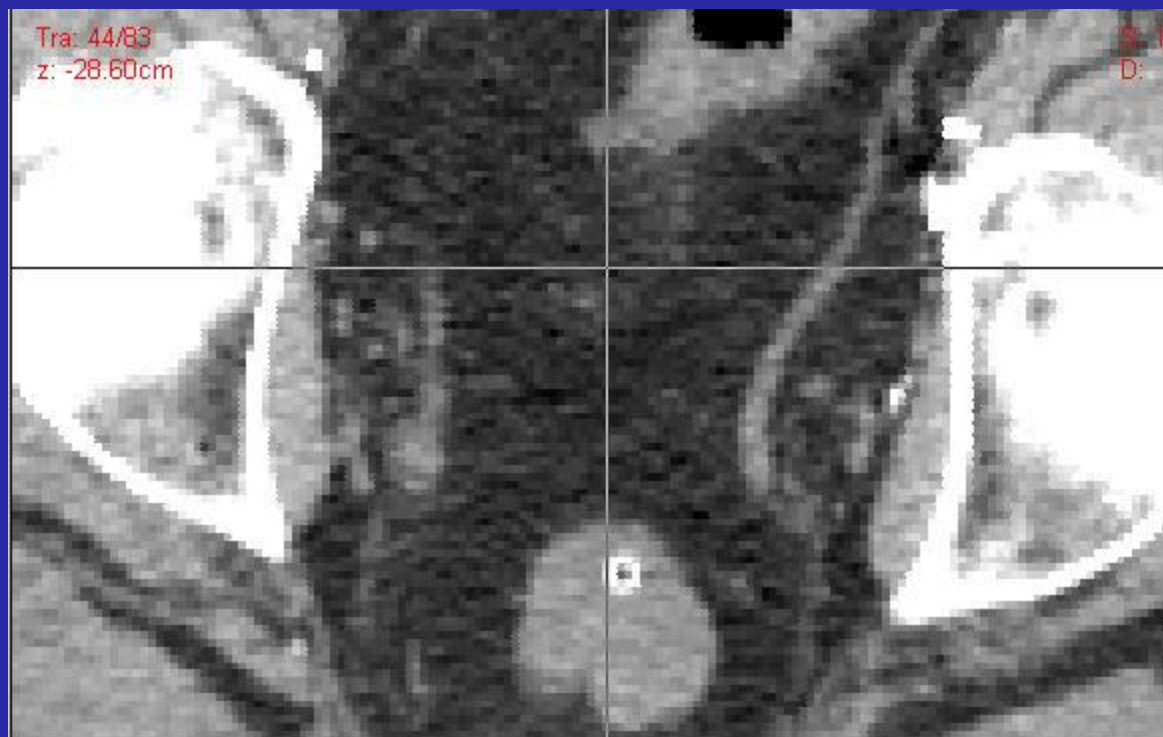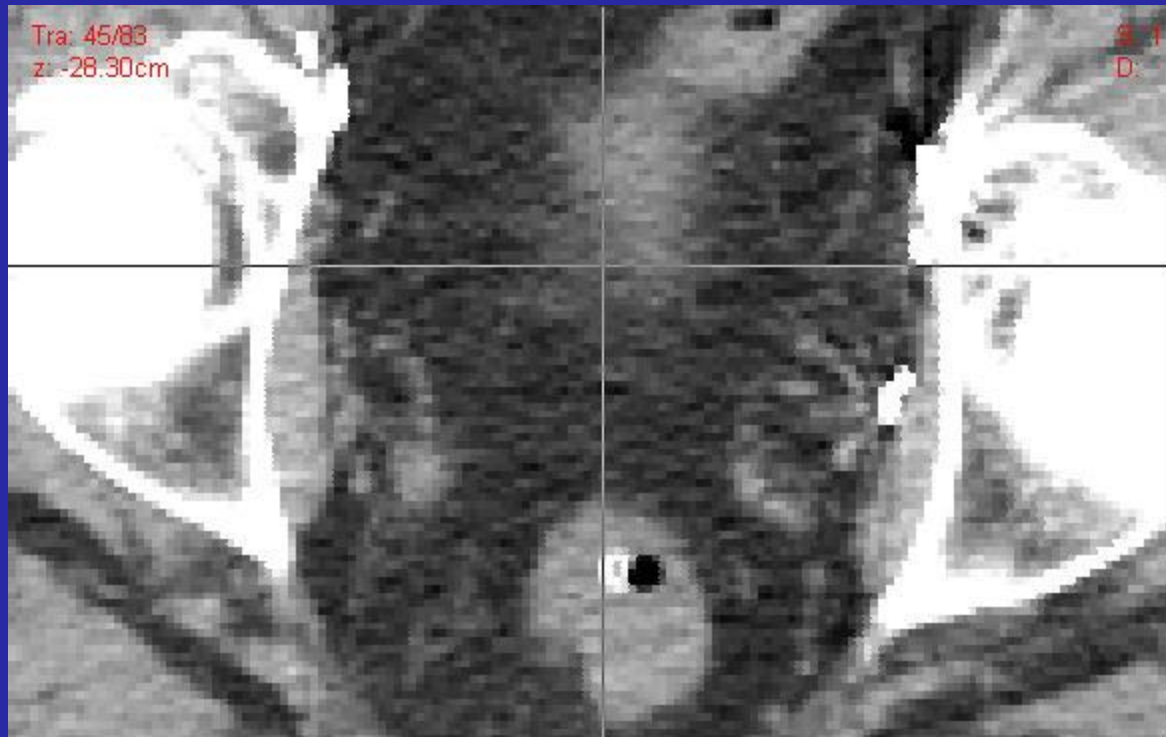


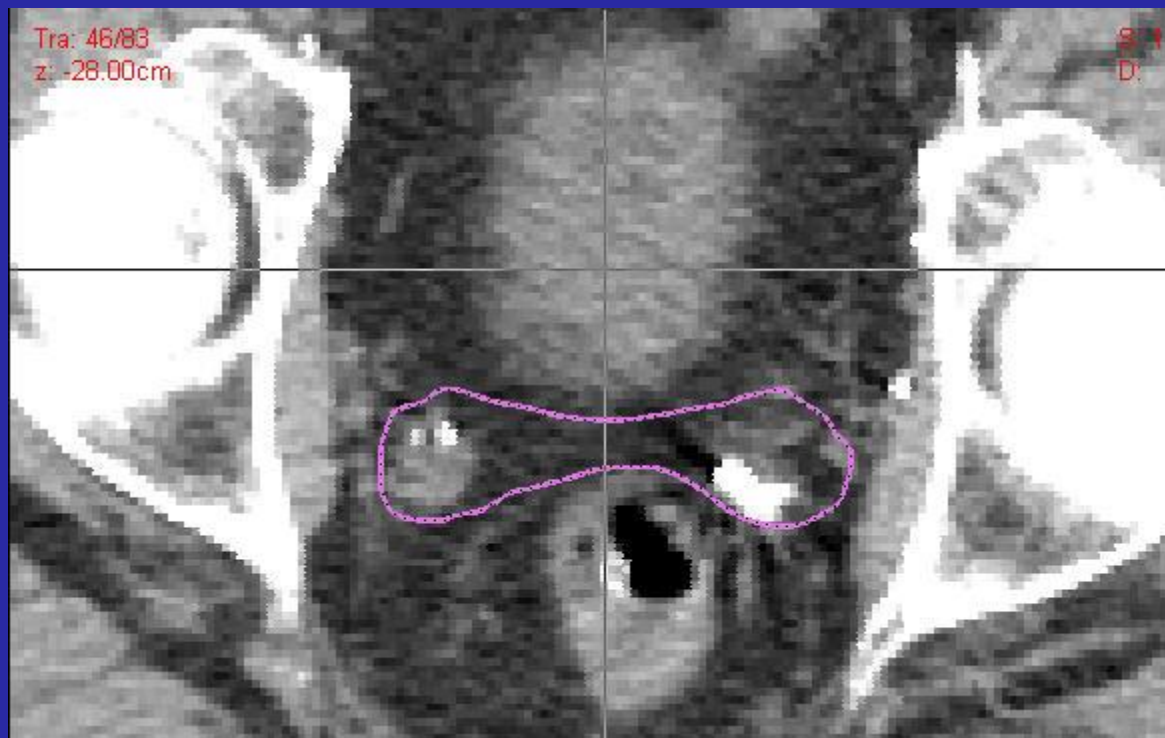Post Op Positive Apex Margins

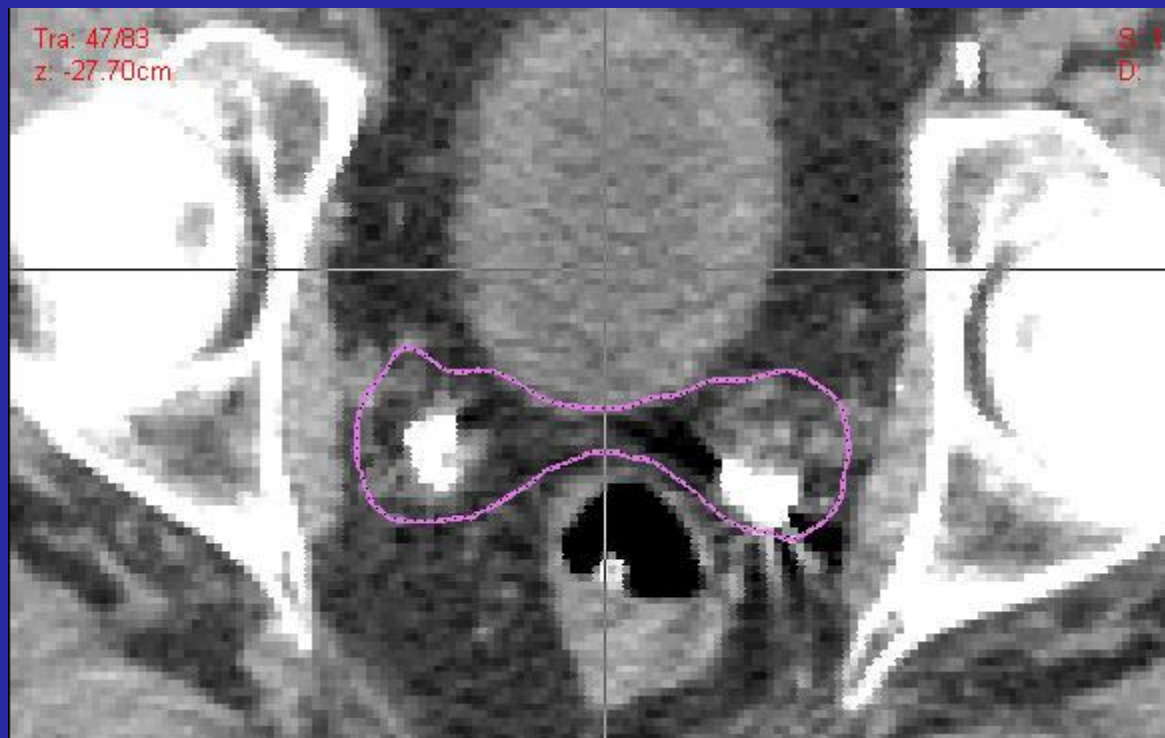Case 3: Prostate_3

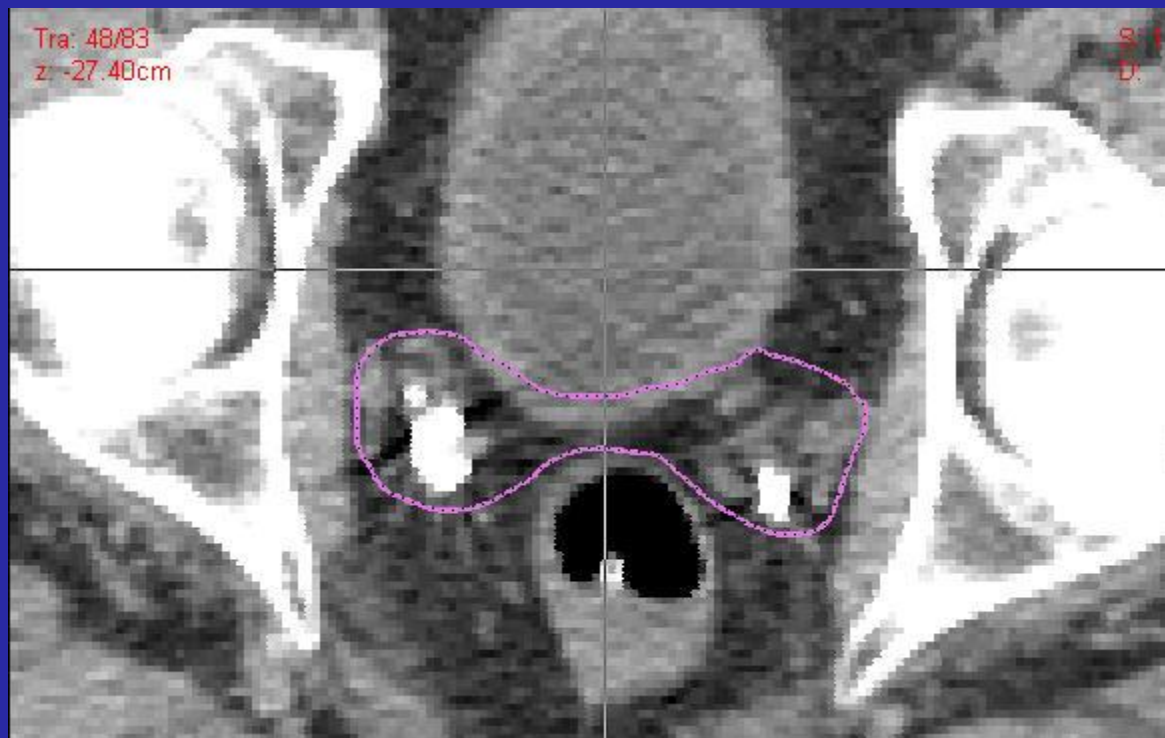
- Case 3
- A 59-year-old gentleman with a preop clinical T1c, Gleason 7 (3+4) PSA 12 adenocarcinoma of the prostate. He is status post radical retro pubic prostatectomy and found to have pathologic T2c, Gleason Score 7 (3+4) disease. Pathology reveals margins positive bilaterally at the apex. His PSA went to undetectable for 2 years then rose to 0.2 and 6 months later was 0.3 ng/ml. Please draw the CTV-TB (CTV for the tumor bed/prostate bed for this case).

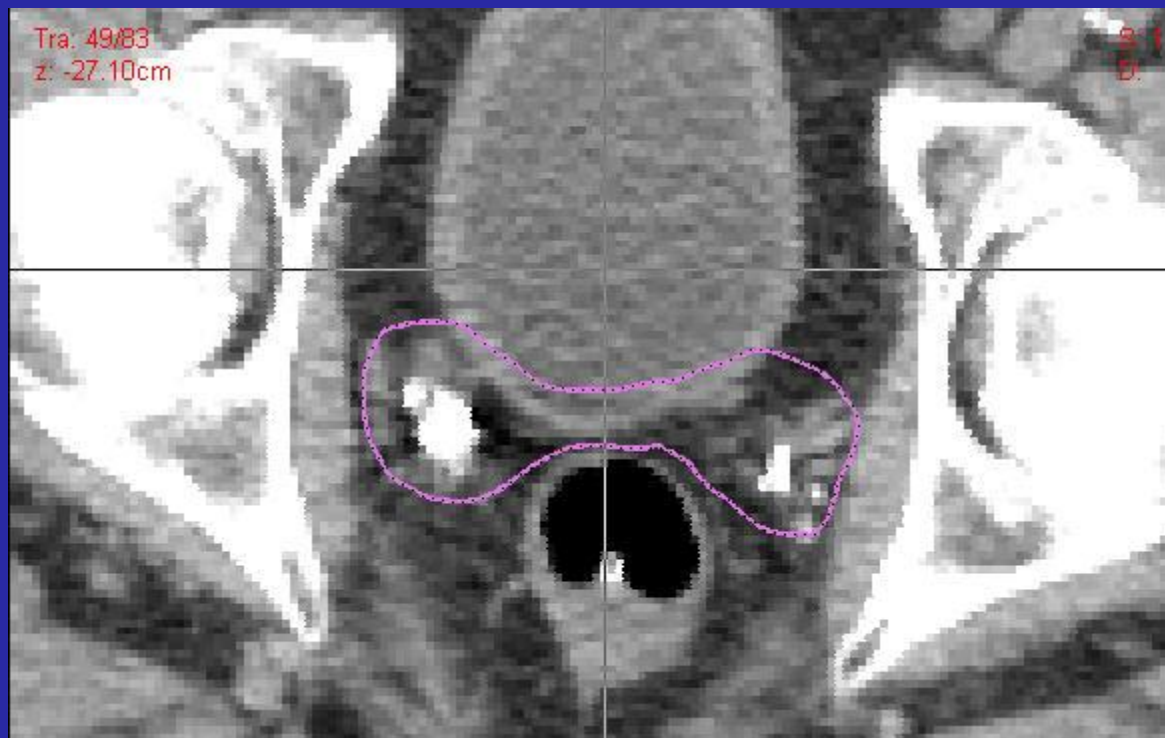

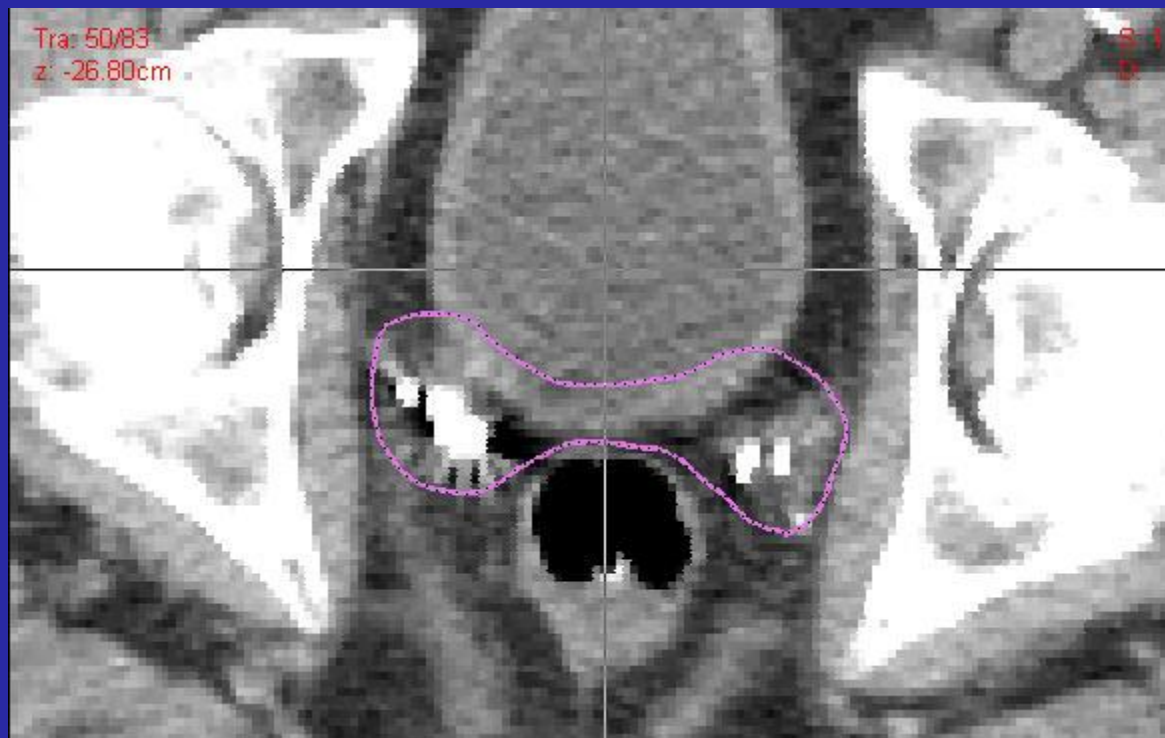



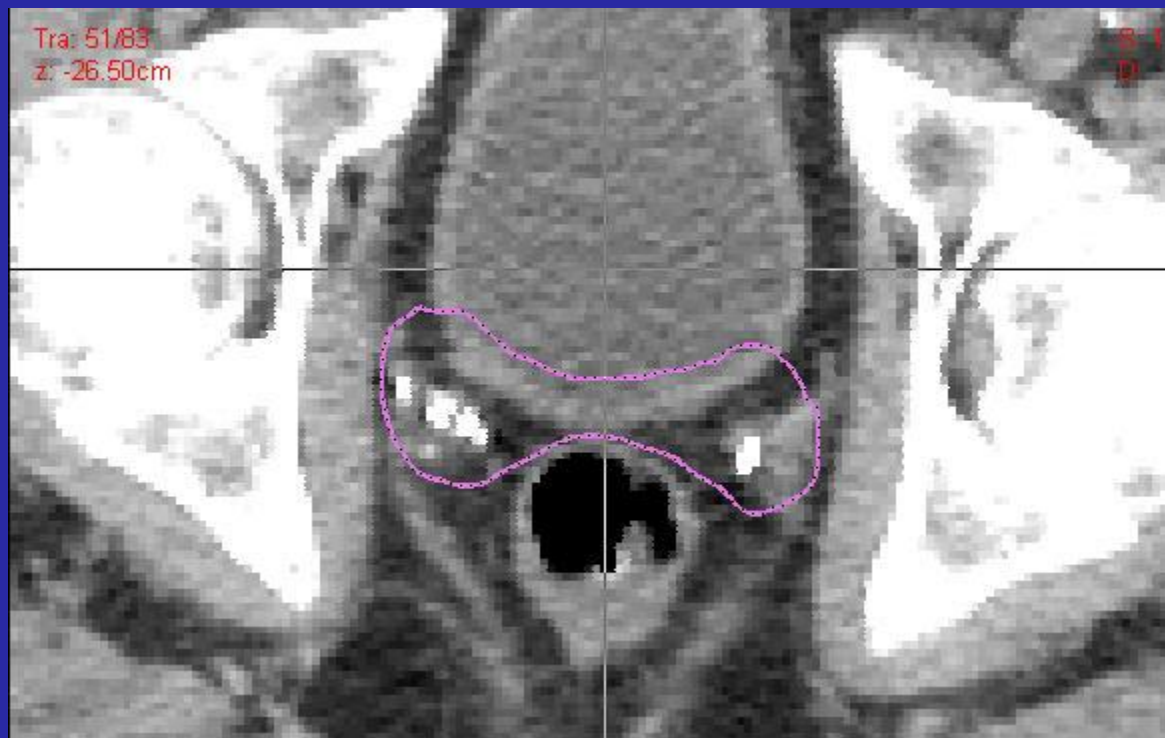
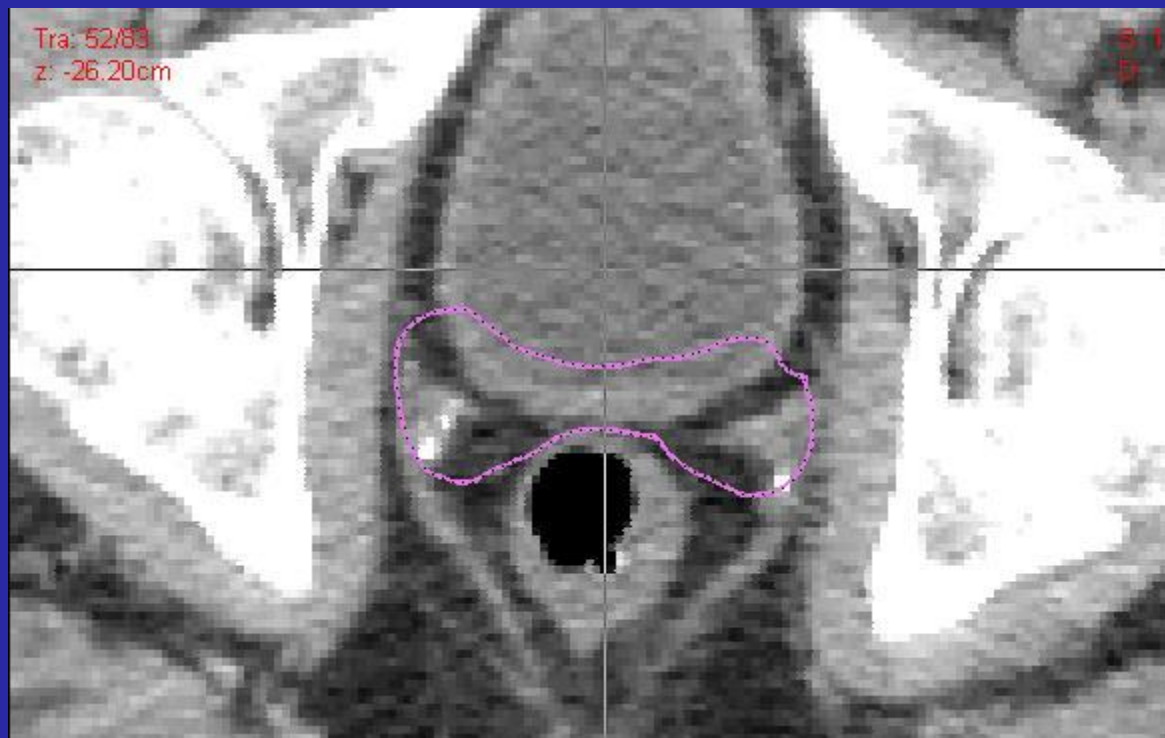




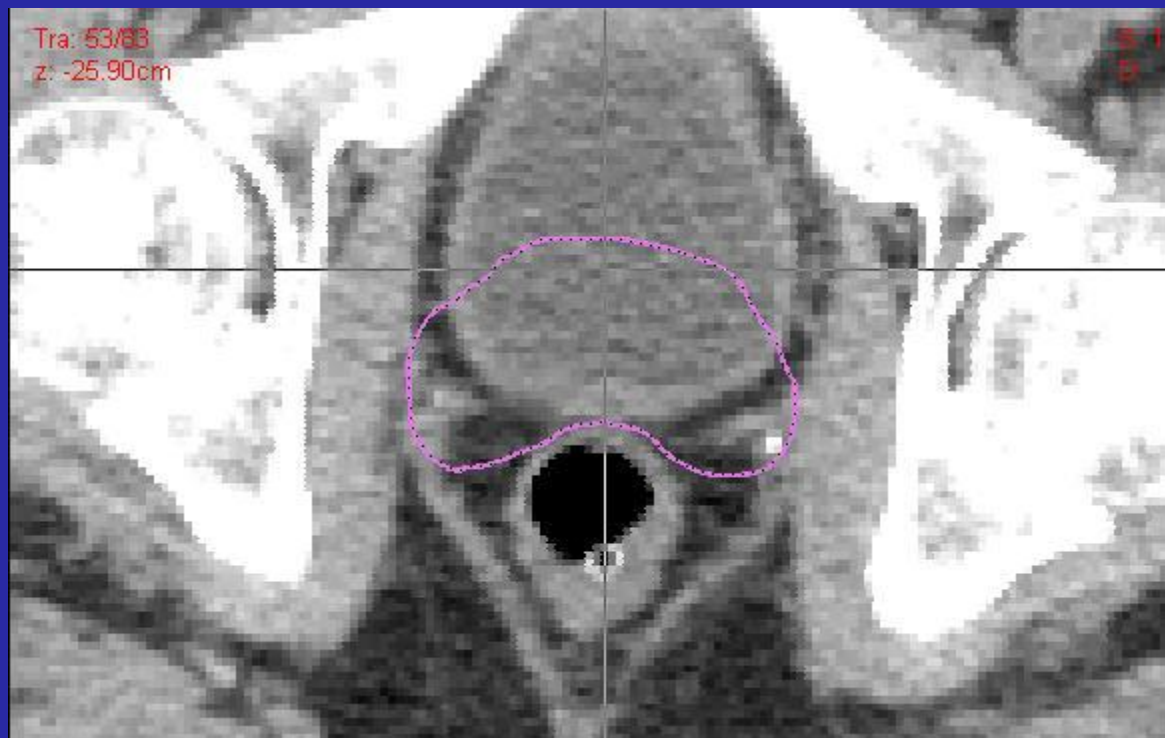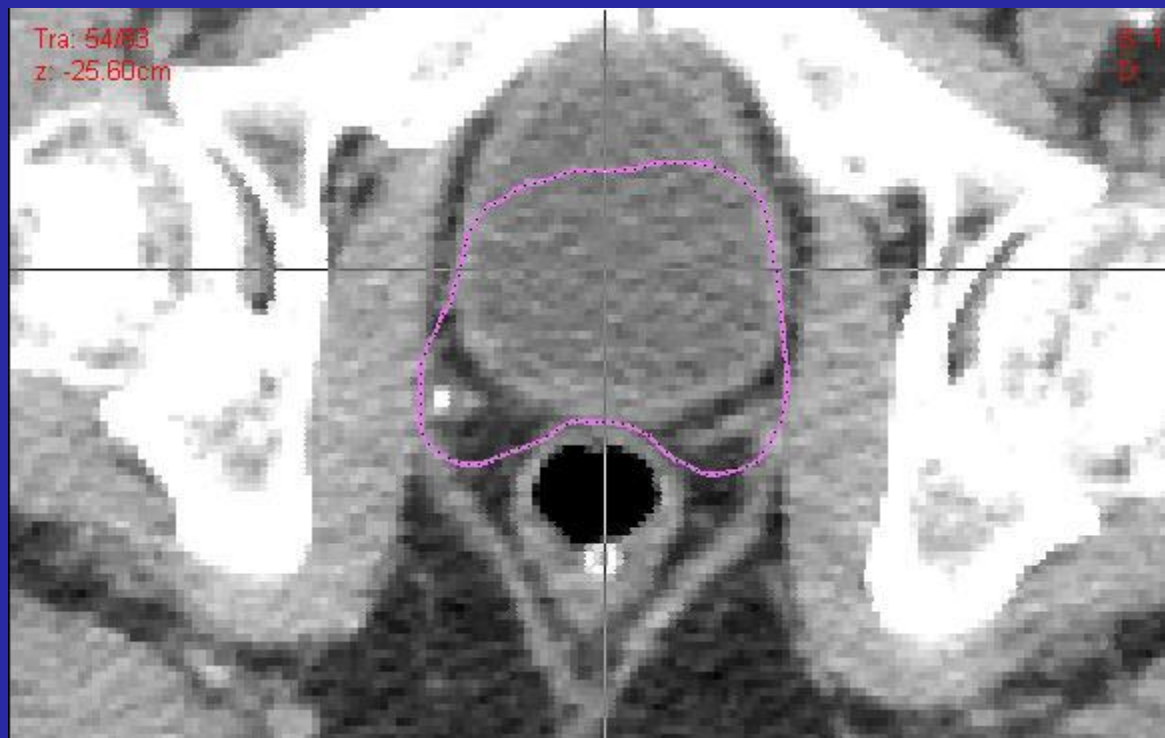


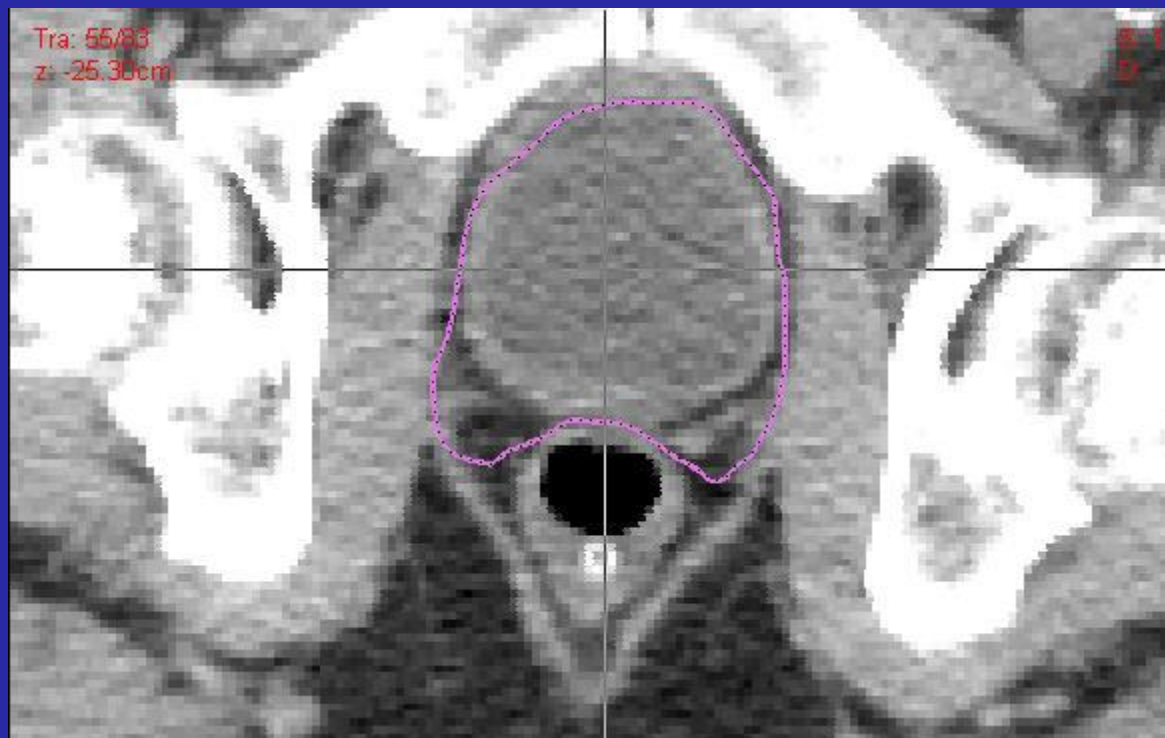


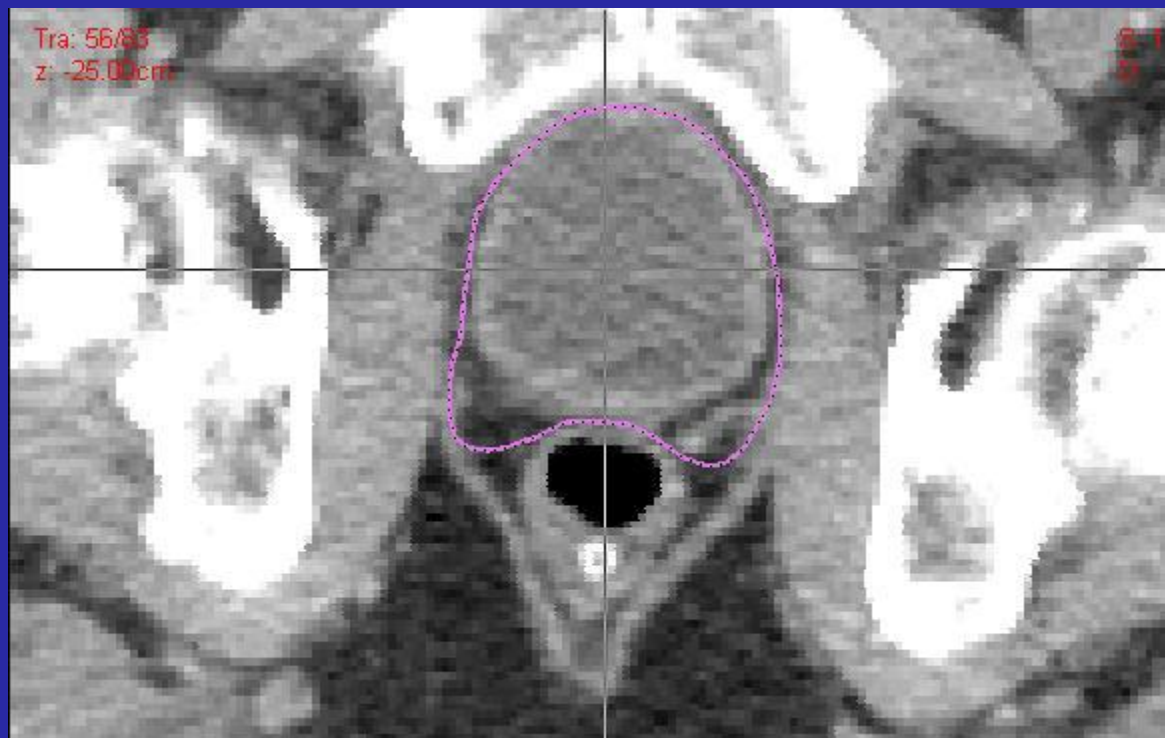


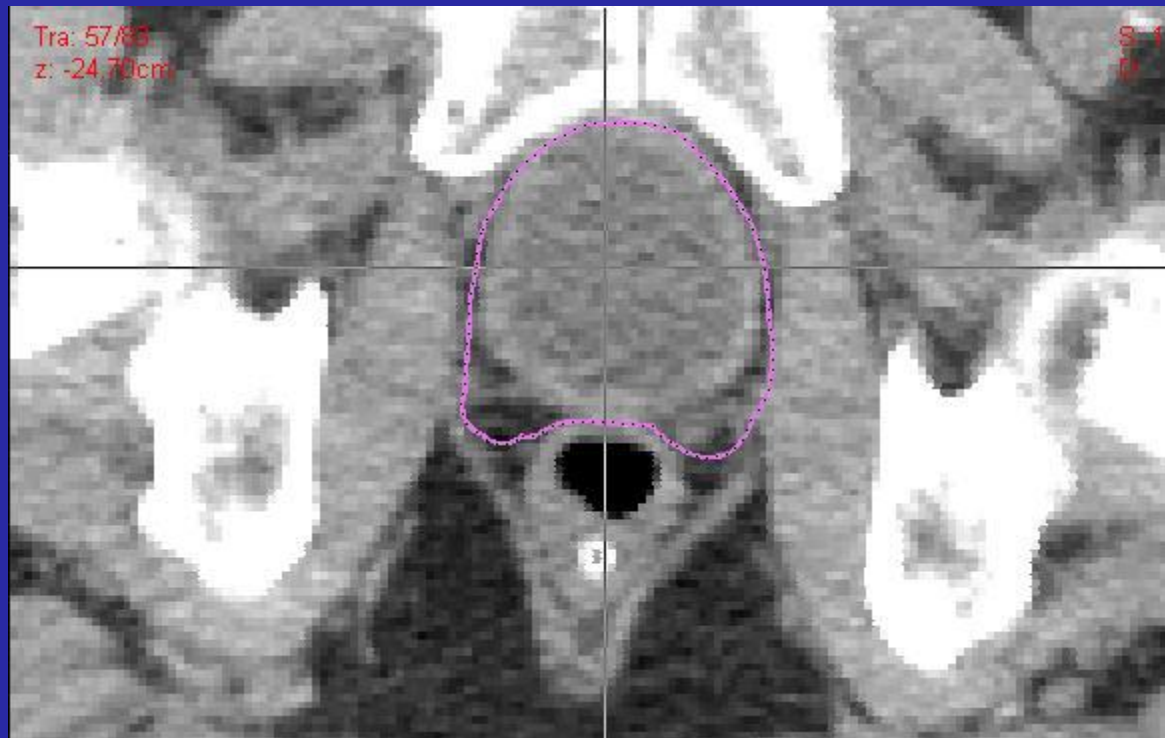




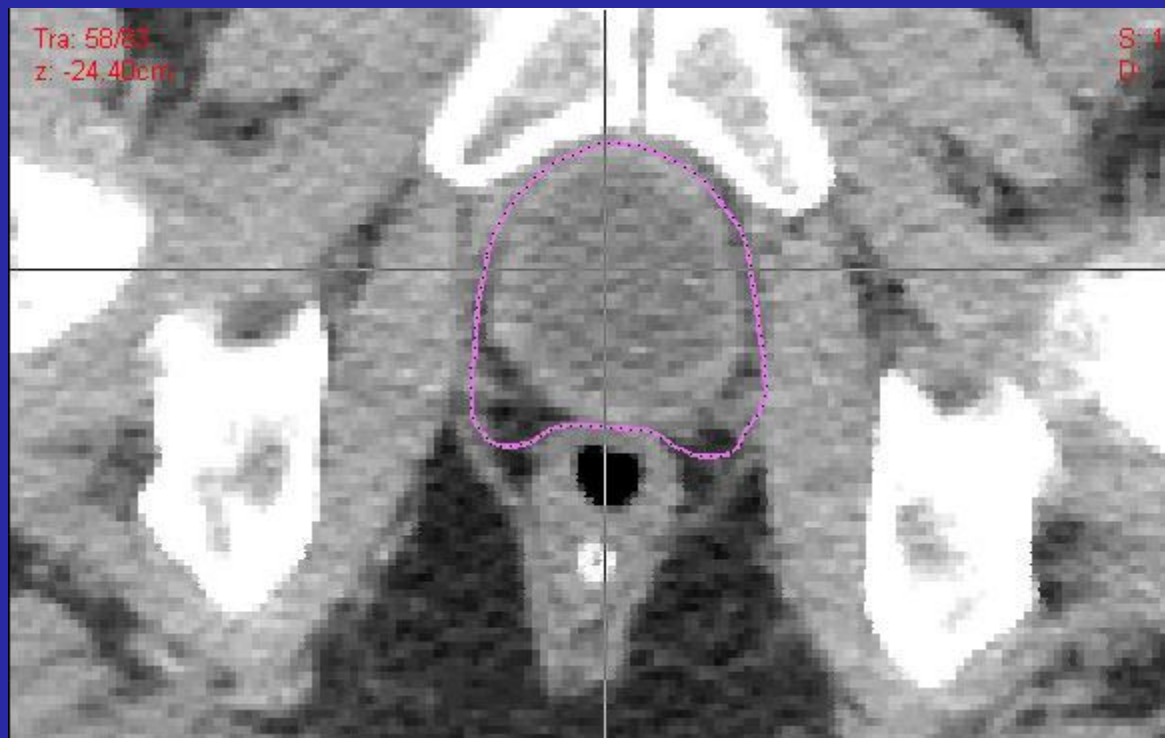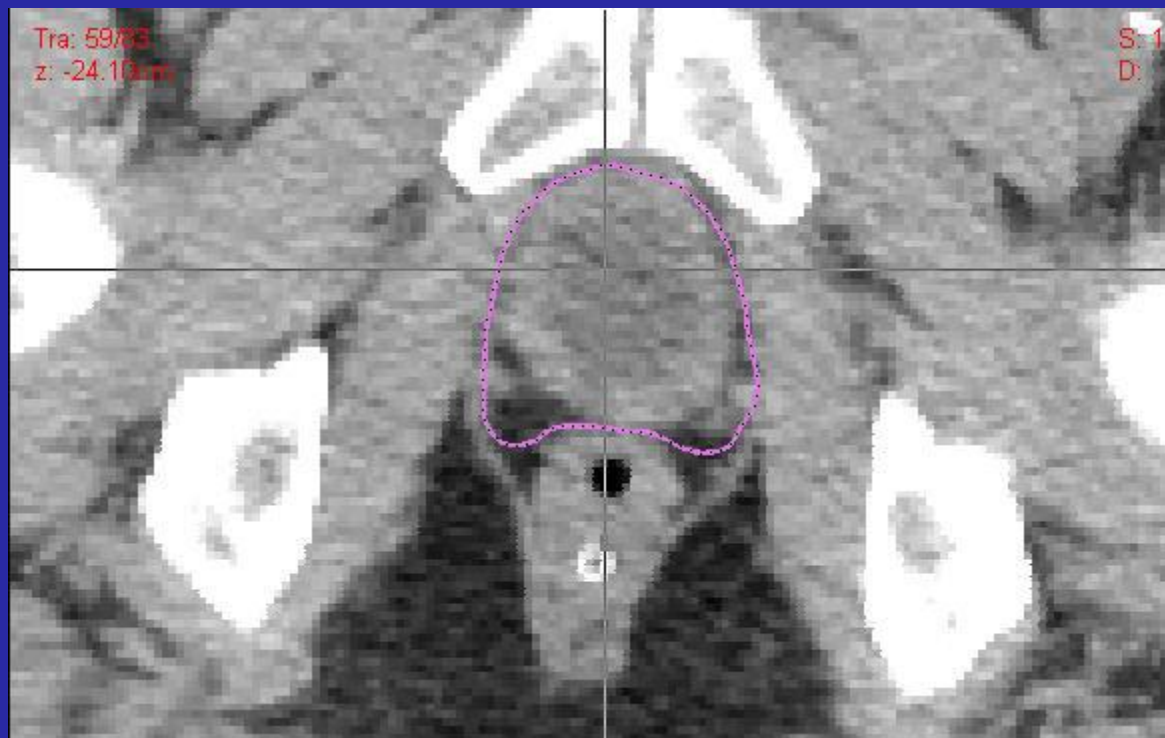




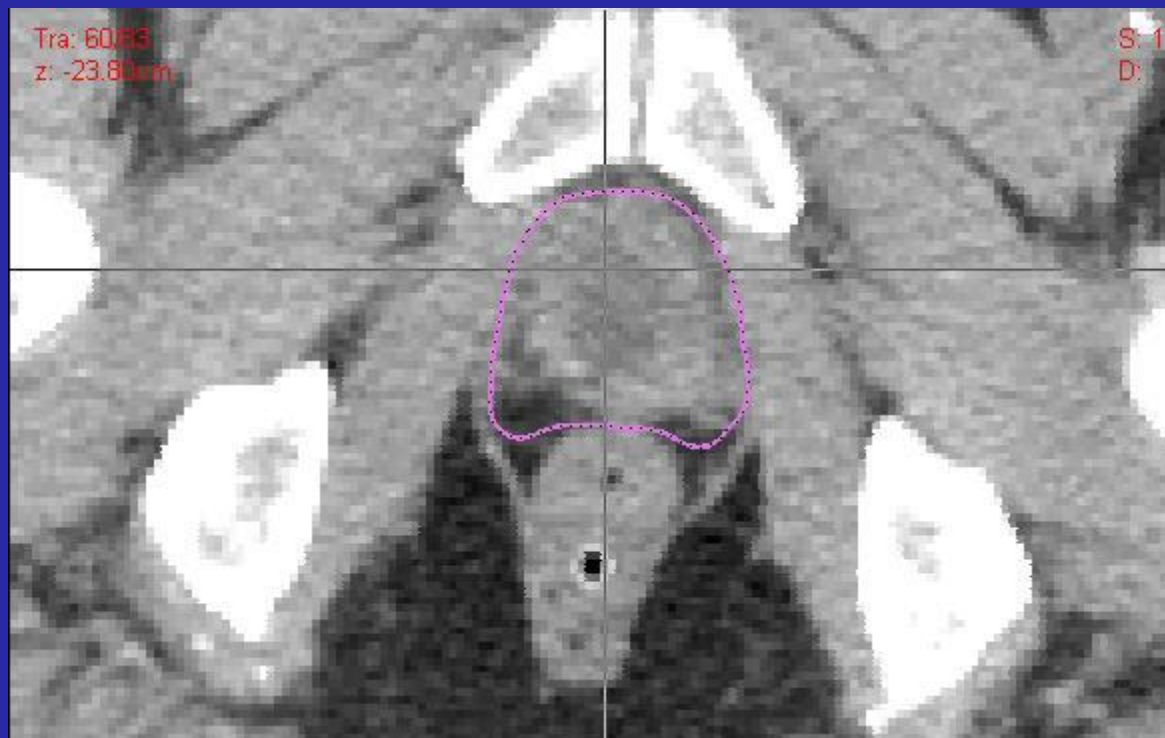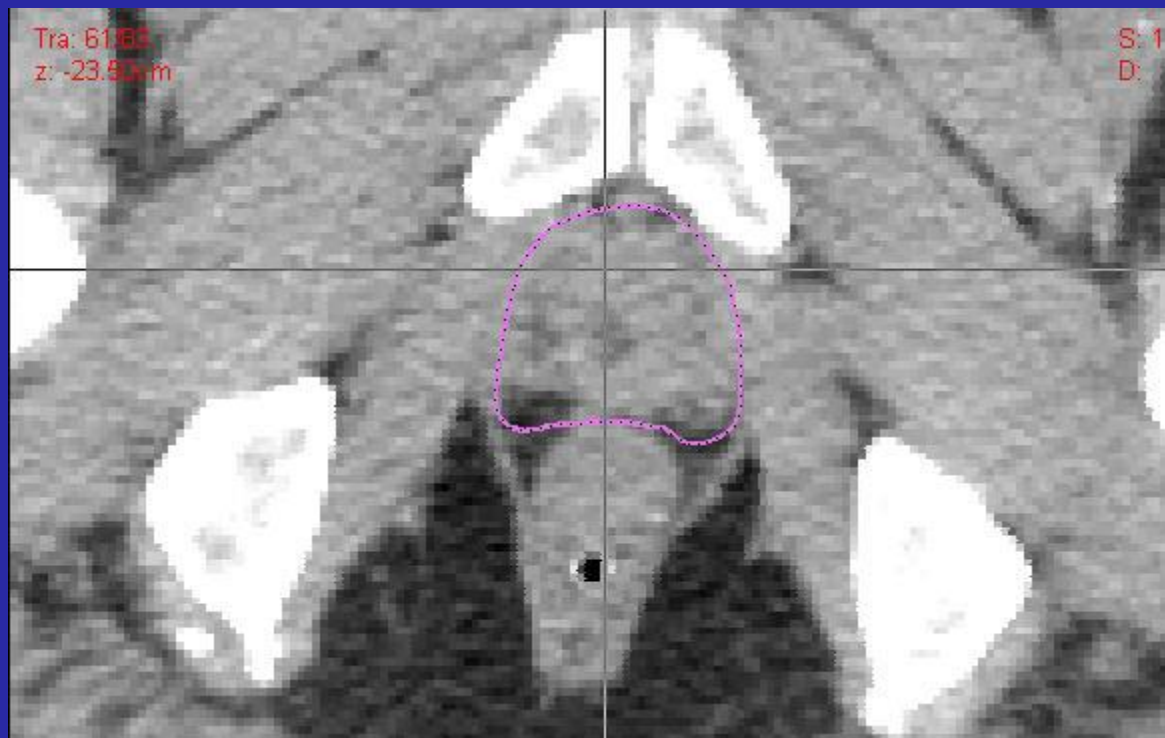


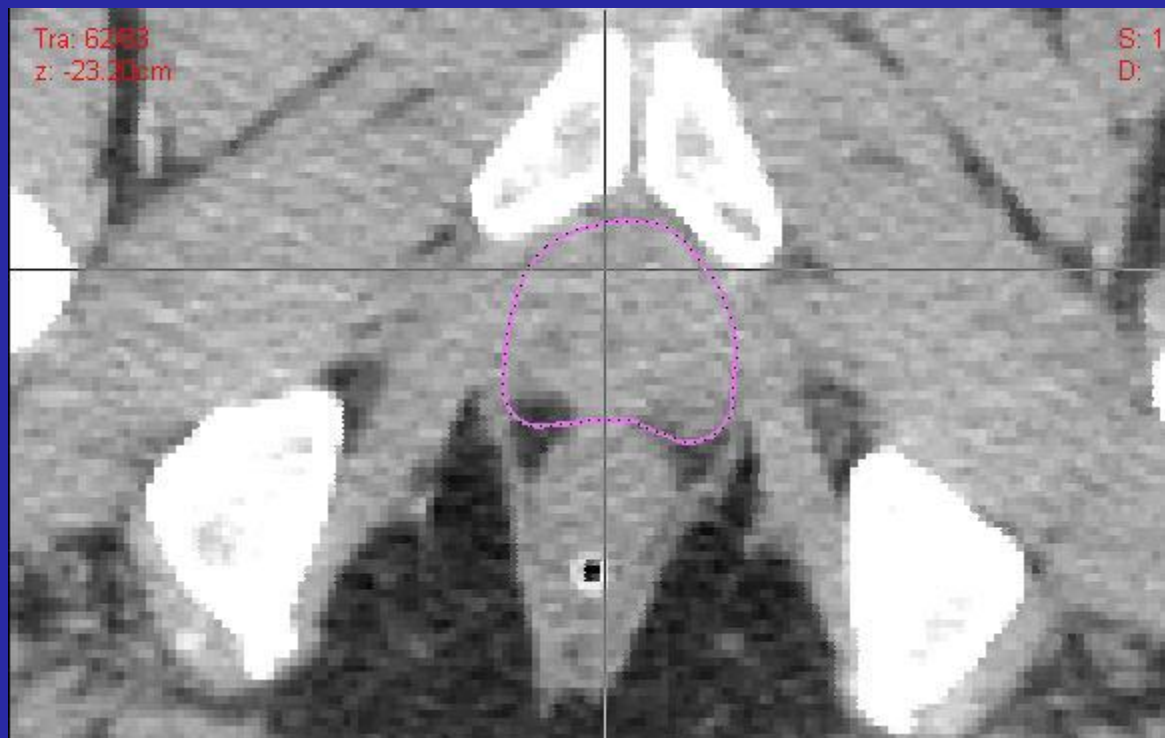


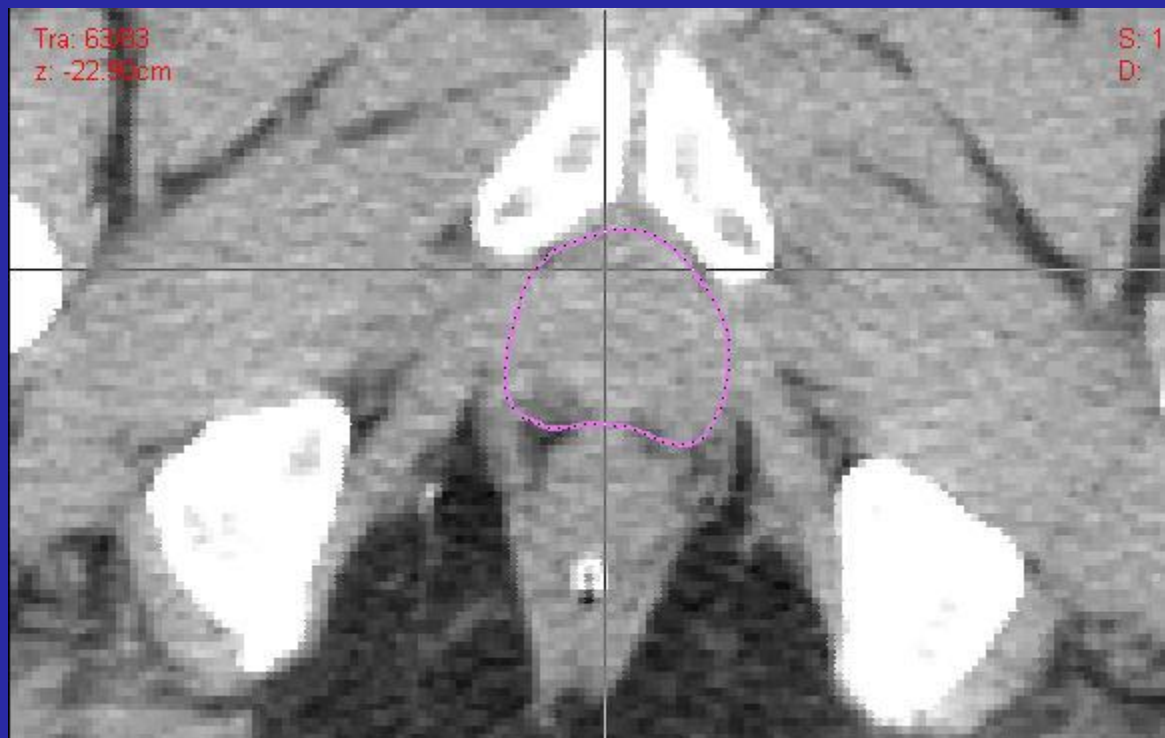







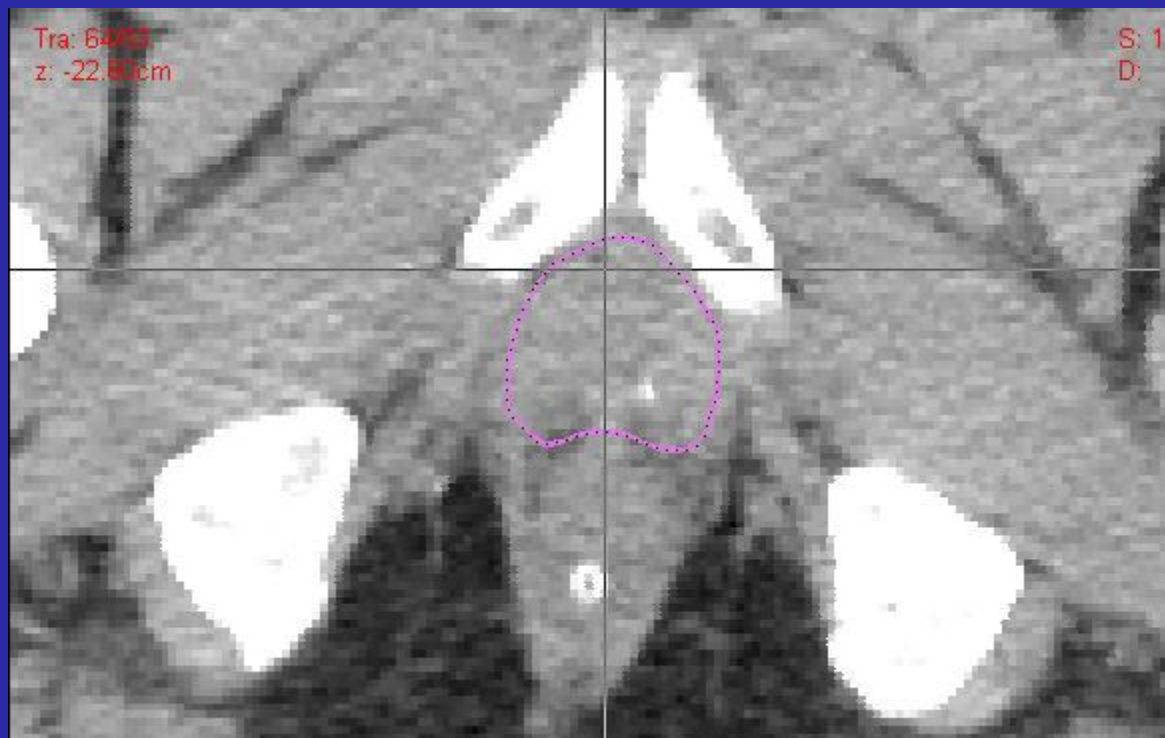
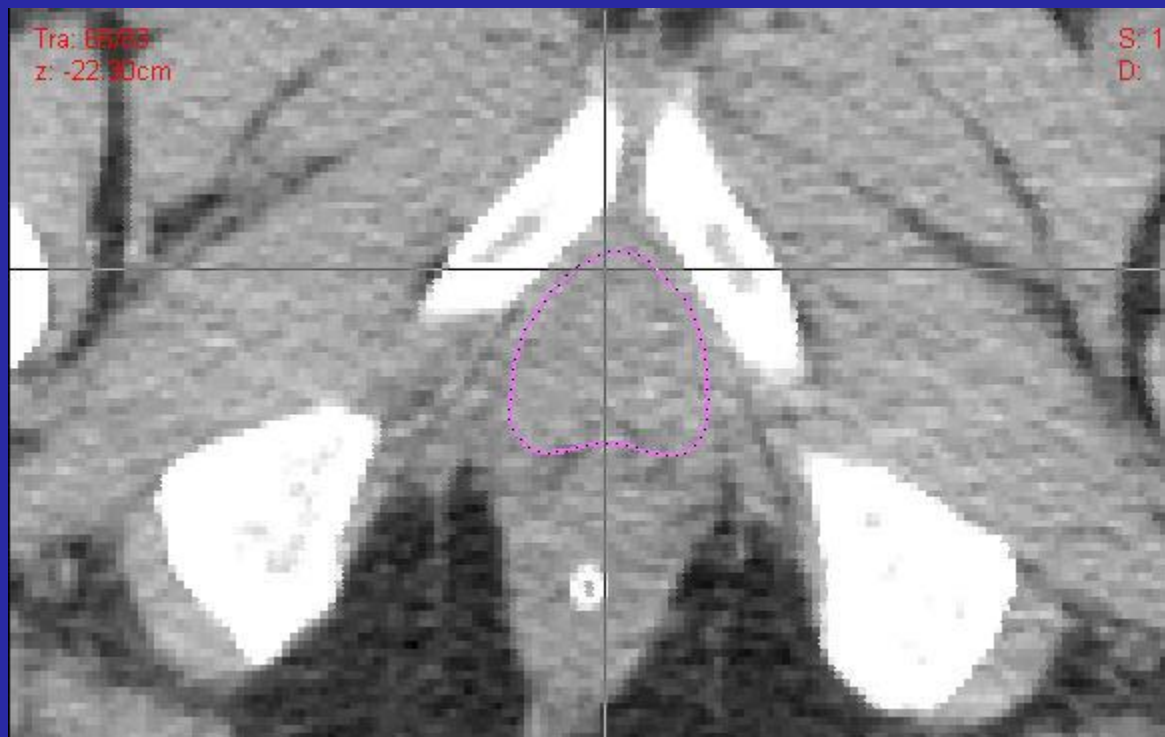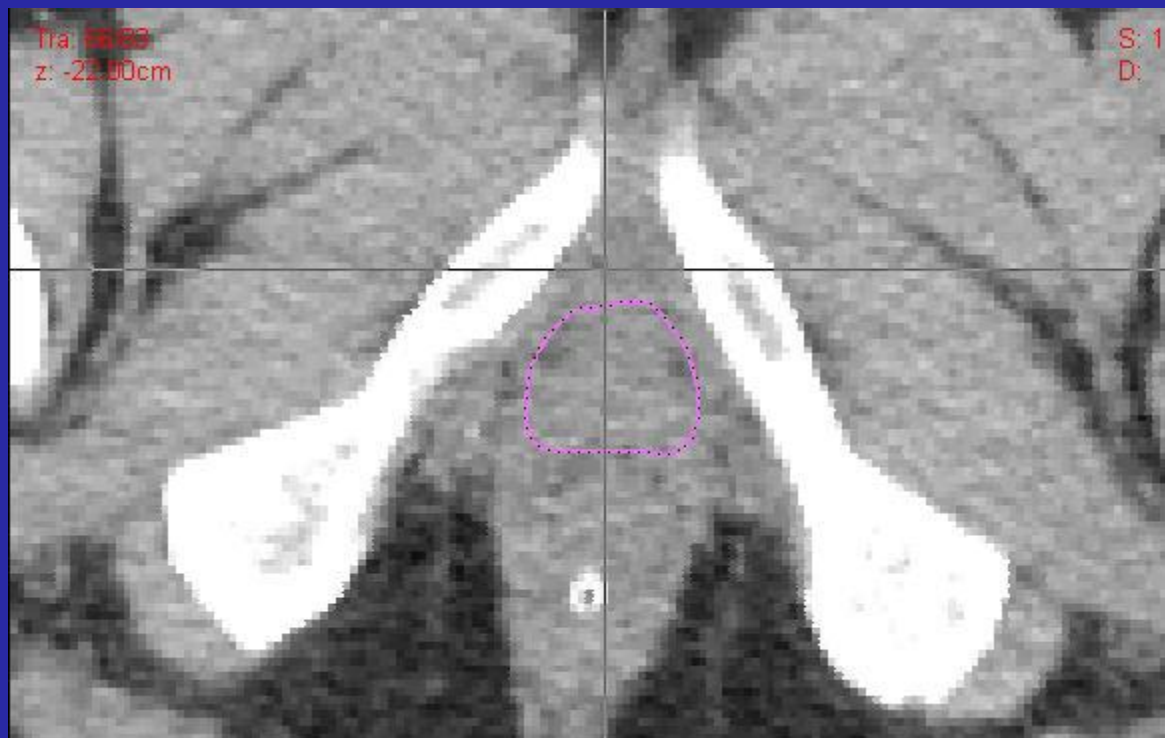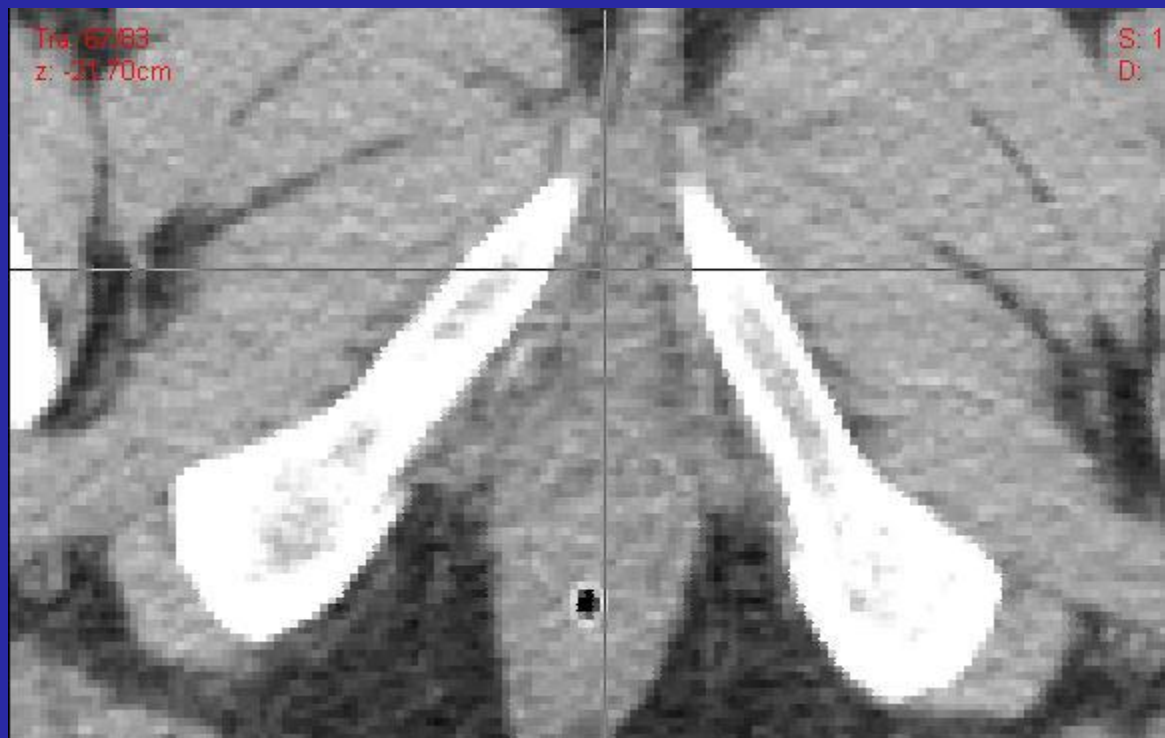


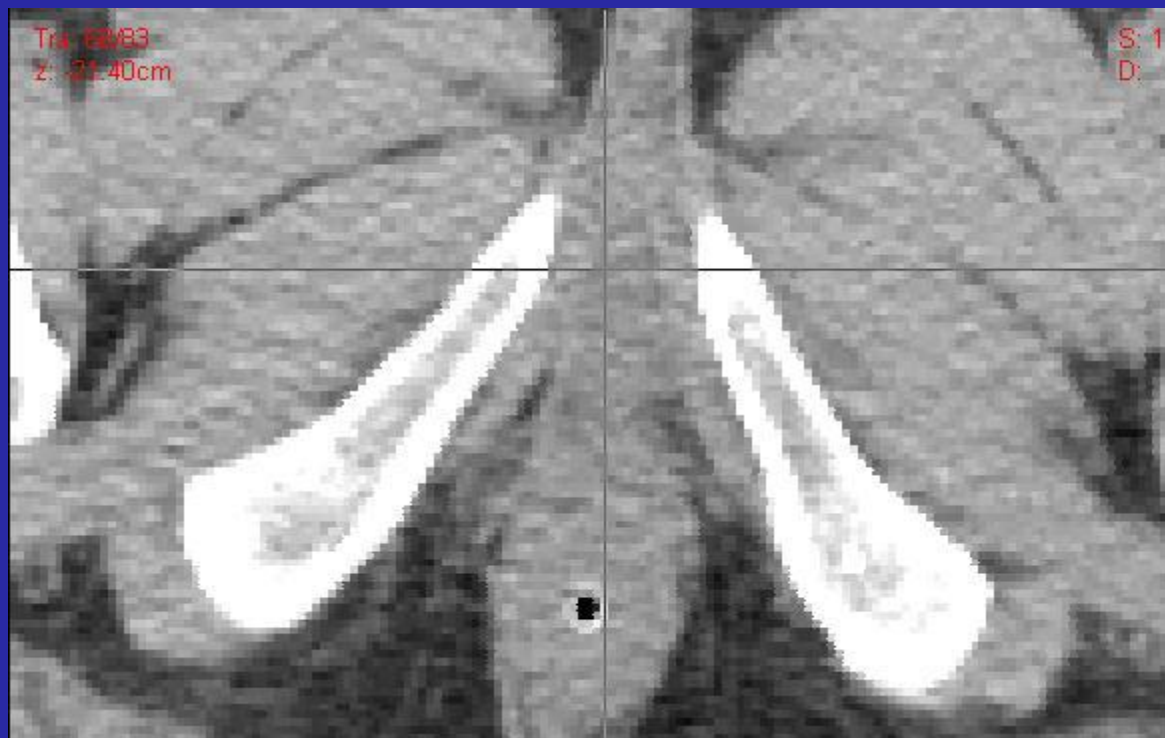


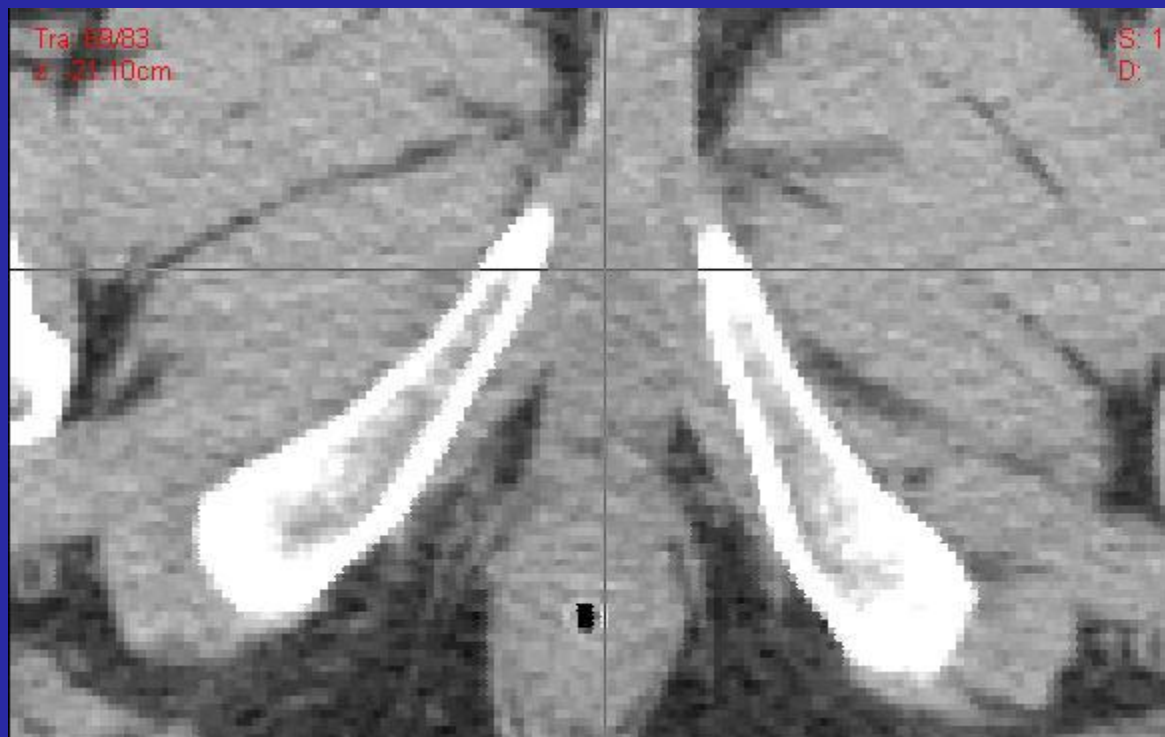


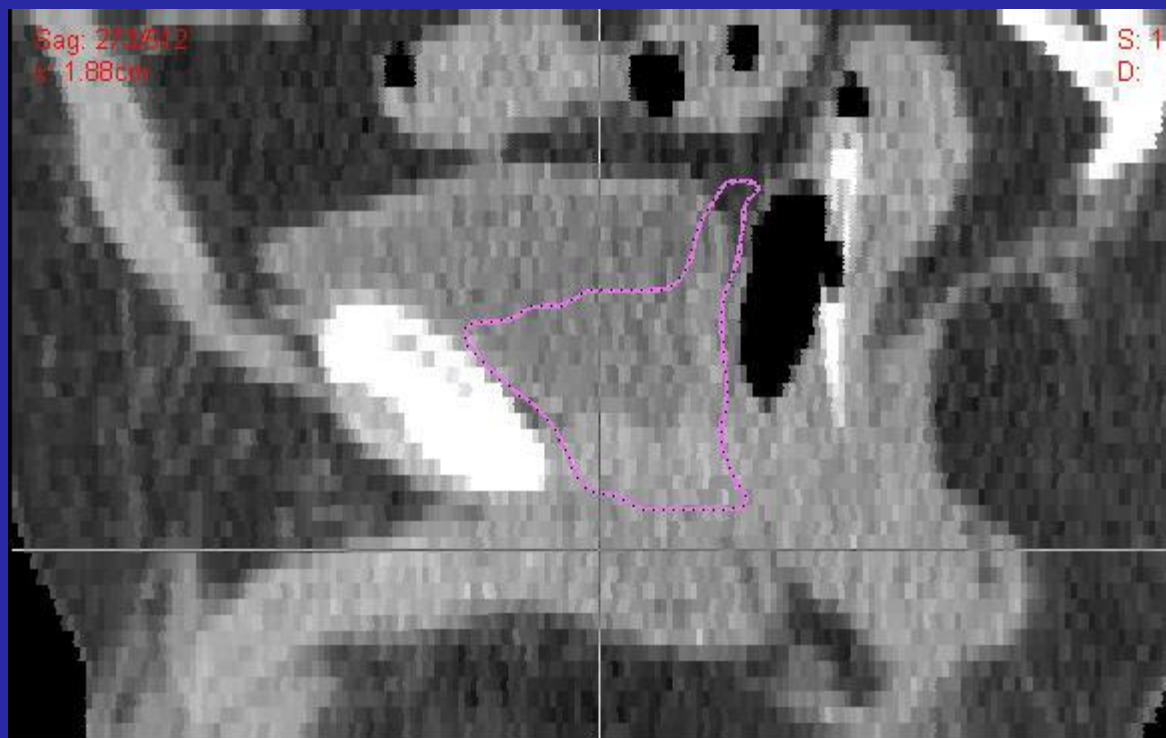


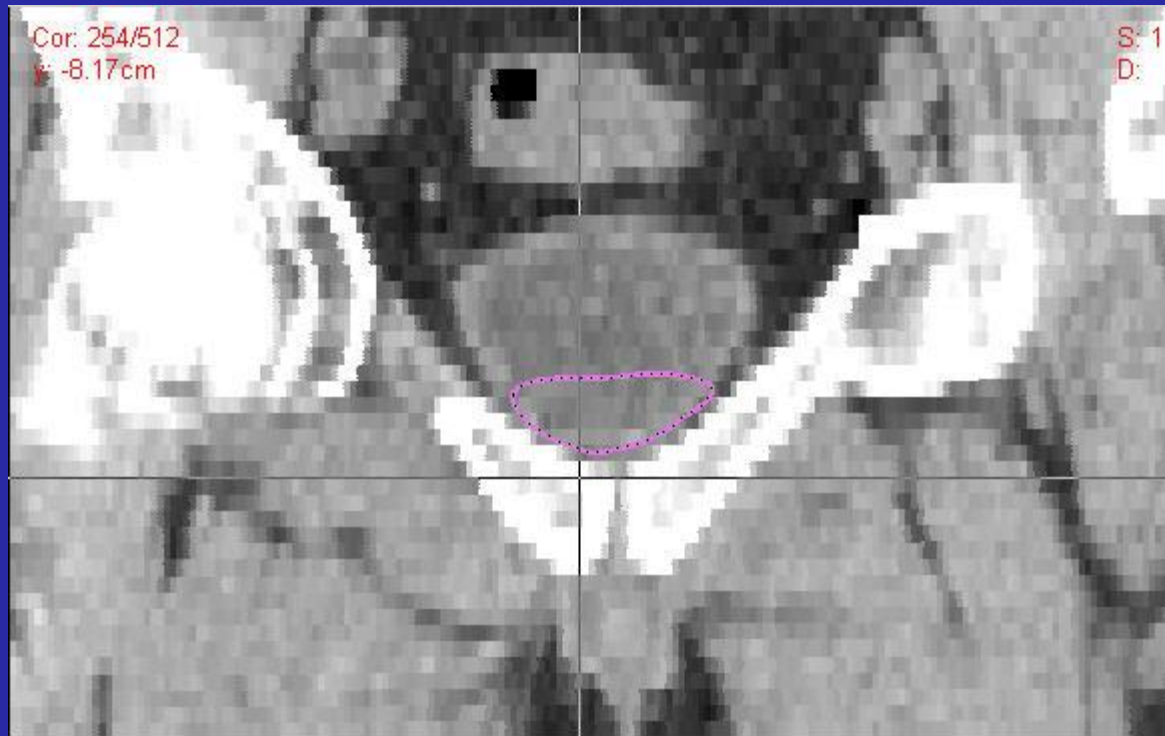




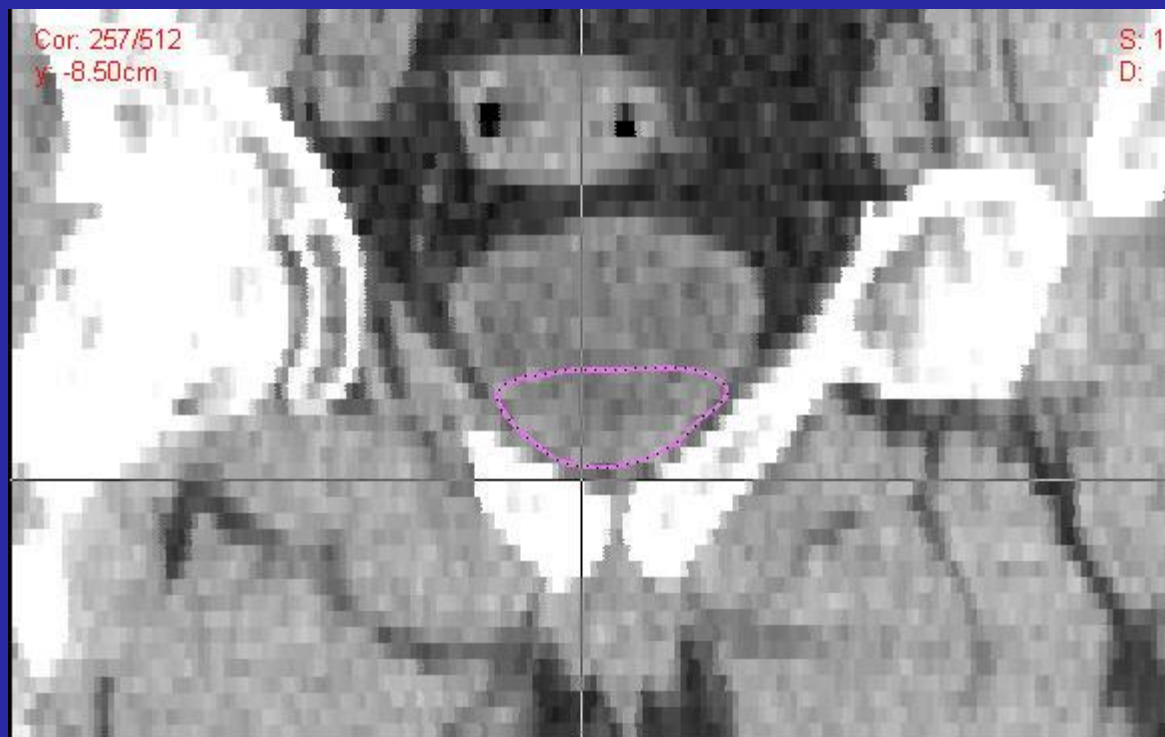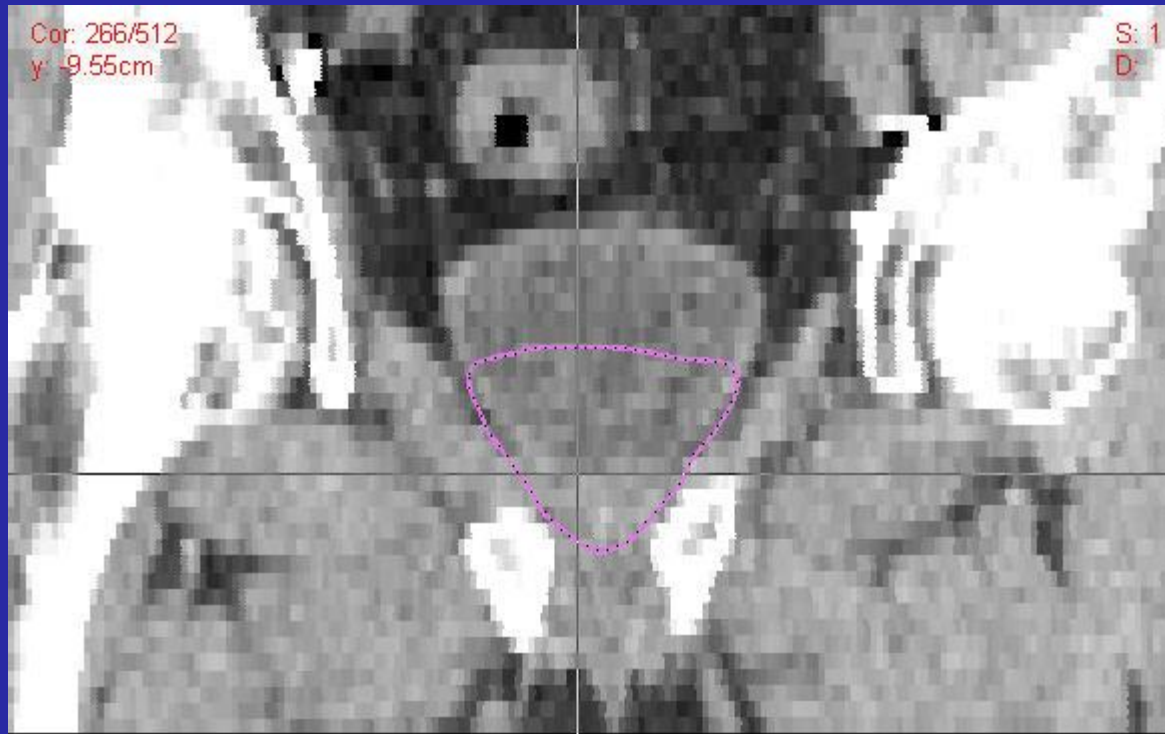


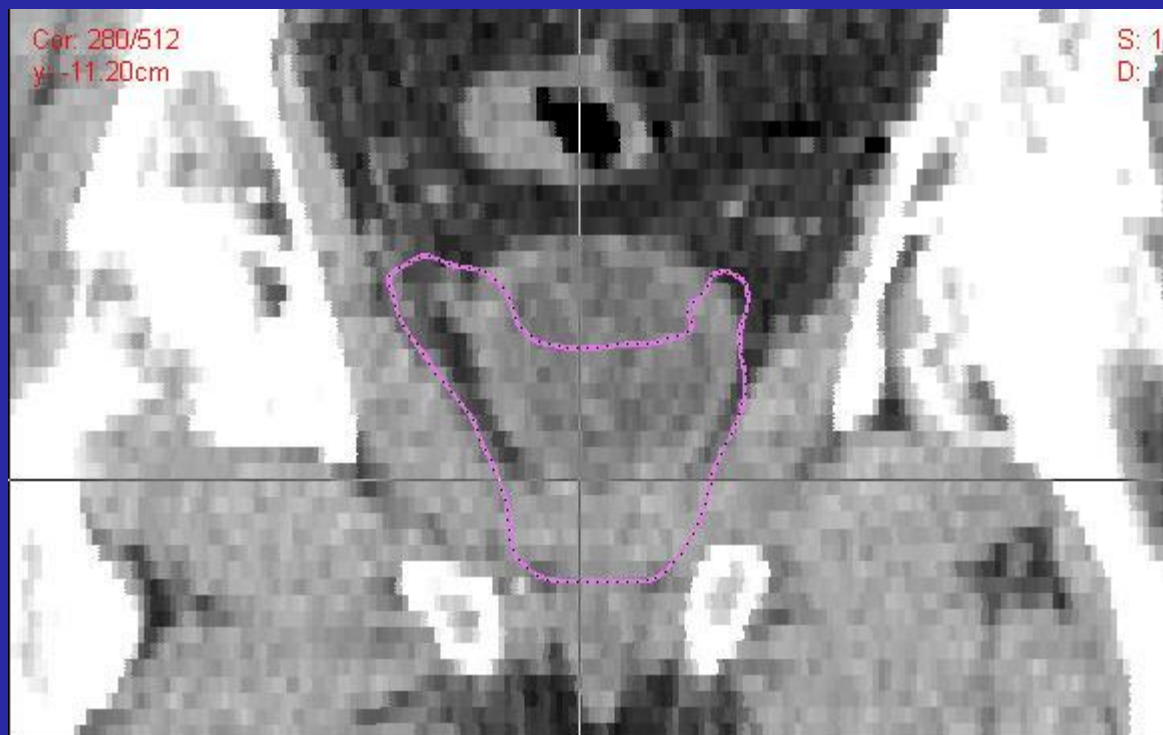


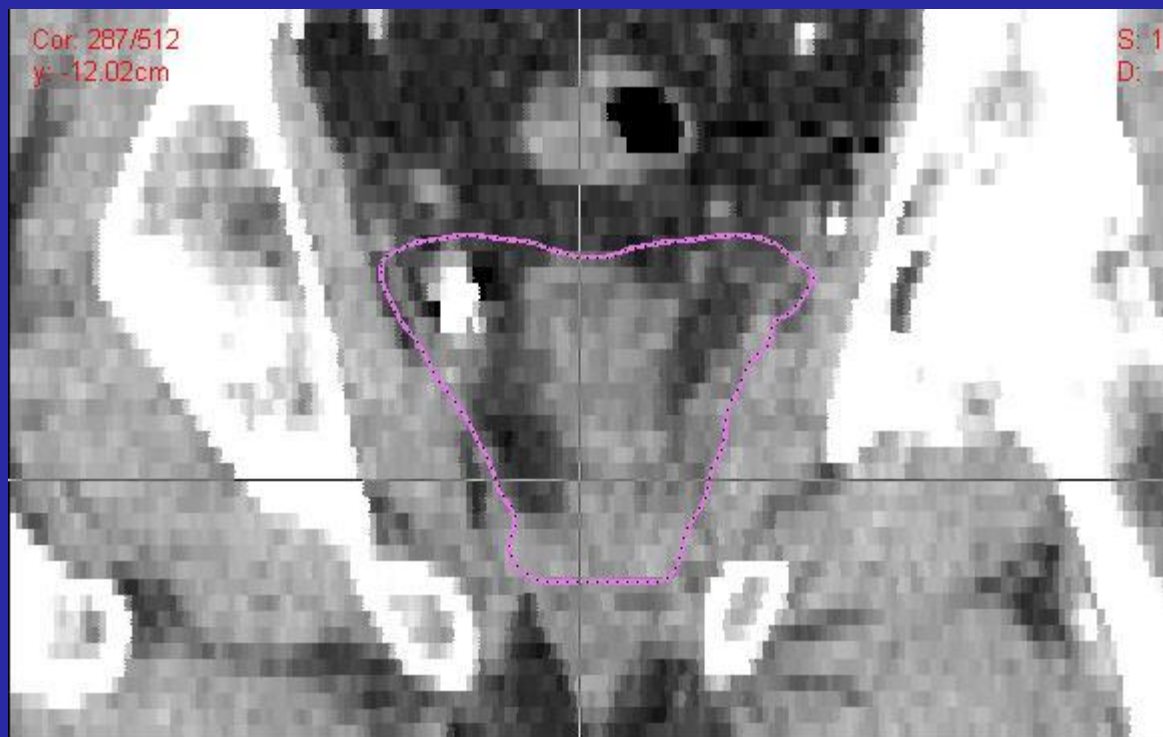












end